



EFCS
European Federation of
Cytology Societies

The EFCS Newsletter



Issue 2/2021



EFCS NEWSLETTER

ISSUE 2/2021



EFCS
European Federation of
Cytology Societies

Dear Friends and Colleagues

We hope this issue of our Newsletter finds you well and safe!

Since approximately 1 year ago, our lives were terribly shaken by a global pandemic.

But one thing is certain: the more we keep pushing and moving forward, the closer we are to returning back to normal.

With this in mind, the EFCS has been dedicated to create new initiatives and projects for all its members and partners. This newsletter being one of them.

We hope you enjoy reading this issue and that you can all learn a little something from it.

Stay safe!

Ricardo Veiga, MD

EFCS Residents and Young Pathologists Committee

In this issue:

- **Very Important Updates on the ECC Congress 2021 and the EFCS Tutorial 2021**
- **Message from Ambrogio Fassina**
- **Case Challenges**
- **Message from the Editor-in-Chief of *Cytopathology***
- **“Odyssey and History of George Papanicolaou’s Scientific Life”, by Maria Nasioutziki**

**For more information about the
EFCS, visit our website!**

<https://www.efcs.eu/>



EFCS NEWSLETTER

ISSUE 2/2021



EFCS
European Federation of
Cytology Societies

UPDATE on the 43rd European Congress of Cytology, Wrocław 2021

Registration for the 43rd European Congress of Cytology (3-6 October 2021) **is now open!** Regardless of the COVID-19 situation, a 100% virtual meeting with high quality informatics support is being prepared for you!

Should the sanitary conditions improve during summer, a hybrid congress will be offered instead, so you all have the choice to attend the event in person!

Follow the ECC website (<https://cytology2021.eu/>) and social media profiles because we are going to prepare you a special discount!

Beatrix Cochand-Priollet MD, PhD, MIAC
EFCS Secretary General

ECC 2021

3-6 October | Wrocław, Poland

43RD EUROPEAN CONGRESS OF CYTOLOGY



For more information about this, please visit
<https://cytology2021.eu/>



EFCS NEWSLETTER

ISSUE 2/2021



EFCS
European Federation of
Cytology Societies

UPDATE on the 12th Annual EFCS Tutorial, Trieste 2021

The EFCS Tutorial goes virtual!!

Due to the persistent coronavirus spread, the “on site” 12th annual EFCS Tutorial, scheduled for June 7th-11th 2021 in Trieste, has been cancelled. We are committed to resume the classic EFCS Tutorials as soon as possible.

In the meantime, **we wish to offer all of you who, a fully online, interactive event, to be held on June 10th-11th 2021!** All the main microscopy sessions foreseen in the original program will be included! Participants will have the opportunity to study in advance a selection of virtual slides and, during the live session, the Tutor will provide a short lecture and discuss the most exemplary slides.

This is a great opportunity for cytologists to participate, in spite of the pandemic, in an event with high practical value. We hope that the event will be a success and ask all the people who love cytology to spread the word and join us!

See you online!

Giovanni Negri MD, PhD, MIAC
EFCS Educational Committee, Tutorials

Arrigo Capitanio, MD
EFCS Educational Committee, E-learning and New Techniques



**For more information and
updates, please visit
[https://www.efcs.eu/12th-
annual-efcs-tutorial/](https://www.efcs.eu/12th-annual-efcs-tutorial/)**

12th Annual EFCS Tutorial





EFCS NEWSLETTER

ISSUE 2/2021



EFCS
European Federation of
Cytology Societies

Message from Ambrogio Fassina

Dear Colleagues,

Being “in medias res”, perhaps you are more aware than us, older pathologists, of how much, and at which level, cytopathology is taught in academies and hospitals. Indeed, although cytopathology represents approximately 30% of the overall routine workload, not everywhere this is encountered by an equivalent residency training program. Thus, the achievement of specific competences and expertise in the field of cytopathology is limited to practical field-experience or based on colleague’s teaching and the participation in tutorials.

From its very beginning, one of the EFCS missions, and maybe the most relevant and carefully taken care of, was (and is!) the organization of tutorials, for which generations of young pathologists are indebted to those members of our Committee who served with enthusiasm and dedication in the preparation of slides and lectures. The EFCS Tutorials have also a follow-up in the delivery of a final assessment with the “Quality Assurance, Training and Examinations Exam” (QUATE, <https://www.efcs.eu/quate-introduction/>), which so far has no legal value, but serves as certification to the fact that the applicant has taken part in the educational activities and has demonstrated skill and competence in reading slides, as well as in answering pertinent questions.

In general, training in pathology takes four or five years, including surgical pathology, autopsy pathology, grossing techniques, molecular, histochemistry, immunohistochemistry, ultrastructural pathology and general cytopathology. Training in ‘areas of interests’, such as cyto-, neuro-, dermatology, cardio- and pediatric-pathology can cover the remaining 12-24 months. Pathologists, who desire to increase their level of expertise and achieve an ‘advanced level of competence’ in a specific field after the general training period, can do that.



EFCS NEWSLETTER

ISSUE 2/2021



EFCS
European Federation of
Cytology Societies

However, generally there is no official recognition or certification of legal value, with the exception of rare realities, such as the specialization in cytology in Croatia and Greece, or neuropathology in the UK. A need for clarification and precise definition exists in other circumstances, such as dermatopathology and gynecological cytology, oftentimes rendered by dermatologists and gynecologists, respectively.

The situation is different in the United States and in Canada, where specific programs grant the interested the possibility to achieve professionalism and legal recognition of their activity in a given area of expertise¹.

The European Union of Medical Specialists (UEMS), Section of Pathology, recommends the harmonization of postgraduate training in Pathology in the European Union (EU) member states and the processes of recognition and accreditation of training programs, and the European Training Requirements in Pathology for Trainees, Trainers and Training Centers have been approved by UEMS General Assembly².

Moreover, in the last years, the European Society of Pathology (ESP), the EFCS and the UEMS Pathology Section have discussed the emerging role of cytopathology in modern medicine, particularly in the field of oncology. In this specific context, precise results and information can/must be granted to the patient, based on minimal tissue and no danger, for the new pathways to approach biological therapy for specific neoplasia, drawing along the guidelines, which are of unvaluable utility, when correctly followed.



EFCS NEWSLETTER

ISSUE 2/2021



EFCS
European Federation of
Cytology Societies

To succeed, residents must comprehend the requirements of clinicians and drug specificities, master the basic and mandatory standards in diagnosis, molecular pathology, informatics, new hardware, laboratory organization, personnel management, integration of the known “areas of interest”, internal and external quality control, multidisciplinary meetings, continuing professional development, critical evaluation of the literature, and highly competent communication skills to deal with clinicians, patients and their relatives.

Young doctors are well aware of the legal responsibilities and implications of their final diagnosis, but modern Pathology demands that they also be responsible for all the pre-analytical procedures (timing of “warm” and “cold” necrosis, fixation techniques, delivery modalities of material to the lab, registration and informatics, tissue banking, financing, etc) and the post analytical regulations of material preservation and storage, since we all, older and young, must remember clearly that Pathology is the sole and unique place where human tissues can be managed and used.

As you see, you are not going to have much space left for anything else.

1. Weir MM, Boerner SL, Auger M. The Canadian Area of Focused Competence (AFC) in Cytopathology experience: the first four years. J Am Soc Cytopathol. 2016 Nov-Dec;5(6):309-312; Naritoku WY, Black-Schaffer WS. Cytopathology fellowship milestones. Cancer Cytopathol. 2014 Dec;122(12):859-65;
2. https://www.uems.eu/_data/assets/pdf_file/0006/111795/UEMS-2019.44-European-TRaining-Requirements-in-Pathology.pdf.

Ambrogio Fassina, MD
EFCS Treasurer



EFCS NEWSLETTER

ISSUE 2/2021



EFCS
European Federation of
Cytology Societies

**And Now Time
for Our Case
Challenges!**

Case Challenges!

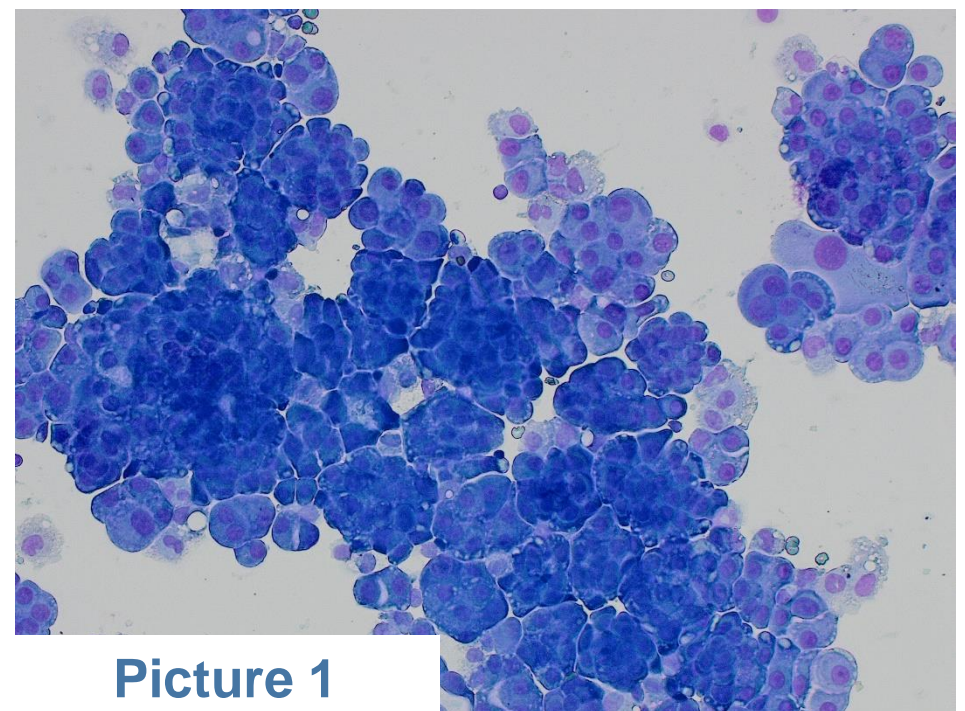
(Answers on the next page!)

1

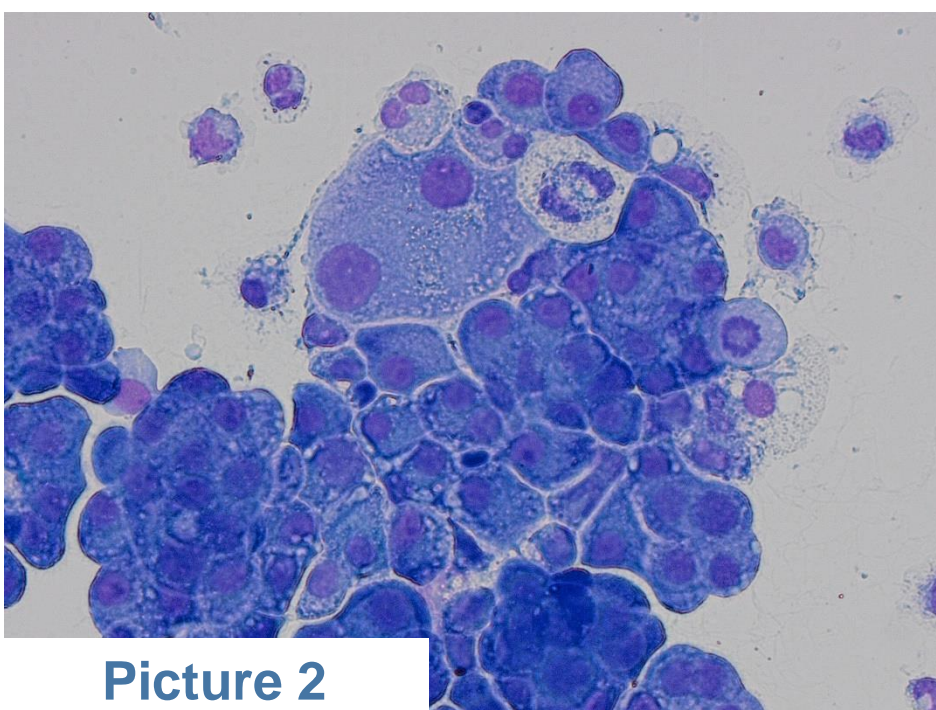
Male patient, 85 years, worked as a miner. He had dyspnea and unilateral pleural effusion. Cytospin cytology sample of the pleural effusion was highly cellular with atypical/malignant cells resembling mesothelial cells (Picture 1 – MGG 200x; and 2 – MGG 400x). On cell block, calretinin was positive (Picture 3, 200x).

According to the Guidelines for the Cytopathologic Diagnosis of Epithelioid and Mixed-Type Malignant Mesothelioma, what approach should be used?

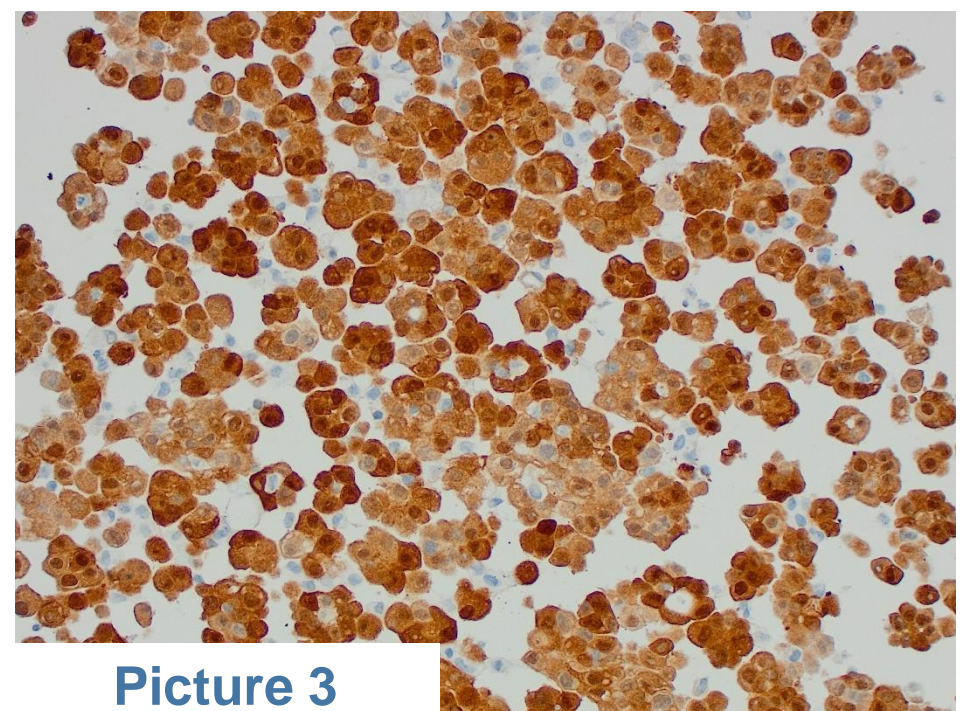
- The information provided is enough to prove the mesothelial origin of the tumor
- It is recommended that a panel of at least four antibodies should be used, two in favour and two against malignant mesothelioma (using cytospins or cell blocks).
- No immunocytochemistry is needed for the diagnosis.
- It is recommended that a panel of at least four antibodies should be used, two in favour and two against malignant mesothelioma (using exclusively cell blocks).



Picture 1



Picture 2



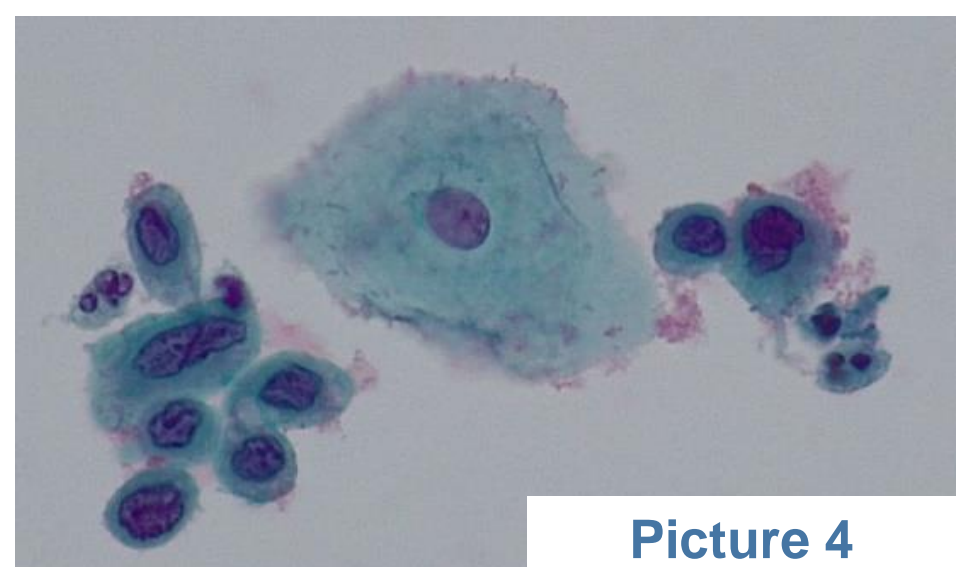
Picture 3

Clinical case and pictures provided by **Danijela Vrdoljak Mozetic MD, PhD**
Chair of the EFCS Educational Committee

2

Cervical cancer screening sample
Age 27
HPV +ve, subtype HPV 16
Thinprep cytology slide prepared (see picture 4)

What does this image show?
What would be the correct management?




Picture 4

3

Cervical cancer screening sample
Age 37
HPV +ve, subtype HPV 16
Thinprep cytology slide prepared (see picture 5)

What does this image show?
What would be the correct management?



Pictures 5.1 and 5.2

Clinical case and pictures provided by **Paul Cross, MD**
EFCS Educational Committee - Quate



EFCS NEWSLETTER

ISSUE 2/2021



EFCS
European Federation of
Cytology Societies

Answers for the Case Challenges

1) Correct answer: B

Danijela Vrdoljak Mozetic MD, PhD

Chair of the EFCS Educational Committee

2) Group of immature metaplastic cells showing high grade squamous intraepithelial lesion (HSIL) (Bethesda), high grade severe dyskaryosis (UK NHSCSP). This would be equivalent to a CIN 3 lesion. Note the abnormal chromatin and nuclear outline, and compare with adjacent normal superficial squamous cell. The woman needs referral for colposcopic examination and assessment, and most likely an excisional procedure, such as a LLETZ (large loop excision of the transformation zone).

3) The image shows candida, with branching hyphae. The squamous cells show some reactive changes in the form of perinuclear halos and a more intense eosinophilic cytoplasm. The candida is the only significant finding from this screening sample. The candida can produce some clinical symptoms but may be purely incidental. If the cytology shows no other abnormality, as in this case, then the cytology is reported as negative with candida present. A follow up sample at 12 months would be advised (in the UK CSP).

Paul Cross, MD

EFCS Educational Committee - Quate

Message from the Editor-in-Chief of Cytopathology

Dear All,

It is a pleasure and honor to announce that I have been nominated for the position of Editor-in-Chief of the journal Cytopathology on January 1, 2021.

The goal is to make the Cytopathology more international by convincing colleagues from Europe and abroad to become new active members of the editorial board and hopefully increase its scientific impact.

As you already know, Cytopathology is the official journal of the British Association for Cytopathology: www.britishcytology.org.uk and an affiliated journal of many national cytology societies through the European Federation of Cytology Societies (EFCS).

With the help of Beatrix Cochand-Priollet, EFCS General Secretary, it is my intention to explore the ways to strongly reinforce the relationship between BAC and EFCS for the entire benefit of all people interested in cytopathology.

Cytopathology




Philippe Vielh, MD, PhD

Editor-in-Chief, Cytopathology

More from this journal, visit
<https://onlinelibrary.wiley.com/journal/13652303>

The Official Journal of the [British Association for Cytopathology](http://www.britishcytology.org.uk) and an
Affiliated Journal of over 20 National
Cytology Societies



**British Association
for Cytopathology**



EFCS NEWSLETTER

ISSUE 2/2021



EFCS
European Federation of
Cytology Societies

GEORGE PAPANICOLAOU

***THE ODYSSEY
AND HISTORY OF HIS
SCIENTIFIC LIFE...***



EFCS NEWSLETTER

ISSUE 2/2021



EFCS
European Federation of
Cytology Societies

GEORGE PAPANICOLAOU – THE ODYSSEY AND HISTORY OF HIS SCIENTIFIC LIFE

“...My ideal is not to become rich or live happily ever after, but to work, to take action and create, to achieve something worthy of a moral and strong human being. All I want is to fight at the front line and either honourably fall or carry the flag of progress to the future.” This is what G. Papanicolaou wrote to his mother during his research/doctorate thesis period at the University of Munich.

George Papanicolaou was born on May 13th 1883 in a small town of Greece, Kymi Evia. His father was a physician and mayor of Kymi. In 1904 at 21, he received his Degree in Medicine (Athens), but he didn't want the conventional career of a practicing physician. So, after his national Army Service (1907), he arrived at Munich for further education and research. (Doctorate thesis in Natural Sciences entitled: “On the conditions of Daphnia sexual differentiation”). Later he worked at Prince Albert I Oceanographic Institute for one year.

In October 1912 the First Balkan War broke out and George Papanicolaou found himself as a Lieutenant in the Medical Corps. It was there that he met Greek-American comrades who talked to him about the opportunities offered in the fields of science and research in the New World. G. Papanicolaou made his decision that he and his wife Andromache would seek an opportunity to make their dreams come true in the United States.

In October 13, 1913, the Papanicolaou couple arrived in New York, with 250 dollars in their pocket - the amount necessary for them to be accepted - without speaking a word of English but full of dreams and guts. In order to make a living they started working at Gimbel's Department Store: Andromache sewed buttons and George sold carpets! In the evenings he wrote for 'Atlantis', the newspaper for Greek immigrants and then played the violin at restaurants!

During the couple's efforts to find a job for G. Papanicolaou in his professional field, they met Dr. Thomas Morgan Biology Professor at Columbia University, New York, who already knew of Dr. Pap's research papers and thought highly of the young man. Prof. Morgan's help was valuable and essential for them.

In October 1914, the young Greek physician entered Cornell Hospital, a place that was to become his home for the next 48 years and the arena of his greatest discoveries and success stories. He soon joined Professor Stockard's research team. G. Papanicolaou worked on studies examining the effect of alcohol on chromosomes – it so happened that it was the period of the Prohibition in the USA. In 1915 a paper of his research was published in Science for the first time and in 1916 more publications about the effect of alcohol on genetic material were made as well as studies on Guinea pigs' vaginal discharge, becoming a well – established researcher at Cornell. It was the time when the researcher was studying animal vaginal cells and their periodical changes with the menstrual cycle.

That was when Papanicolaou decided to turn to human cells and took his first sample from no other than his own wife Andromache. For G. Papanicolaou she was his 'Mache', his 'symbia', which in Greek means his comrade in life. 'Without my wife's help', he used to say, 'it would have been very difficult for me to continue my research'. He used to introduce her as 'my wife and my victim.' Later on he worked with Women's Hospital and paid female members of the staff 1 dollar every time he took a smear from them, at a time when his own salary was a mere 60 dollars a month. It was at that time (1923) that he started recognising the significance of cellular material that had been used and exfoliated from various body cavities. In his studies George Papanicolaou aimed at preserving and studying such cells. This was the beginning of the Pap test, i.e. the smear test. The idea that exfoliated cells are carriers of useful information in early detection of malignancy turned into study methodology.



G. Papanicolaou, his wife, and 5 assistants in the Laboratory with the Lasker Award



Dr G. Papanicolaou always carrying his microscope everywhere, so as not to waste time on research




Prof. G. Papanicolaou training physicians and technicians at Cornell University



G. Papanicolaou in front of his microscope at home



Mrs and Dr. Papanicolaou working in Cytology Laboratory Cornell University



G. Papanicolaou statue at the entry of Cornell University, N.York

G. Papanicolaou later used samples from actual patients and this led to his historic discovery. Among their normal cells, he also noticed 'malignant cells' in vaginal-cervical smears. As he himself said, it was 'the most exciting moment of my life'. In 1928 he made the first announcement on his findings "Diagnosis of Uterine Cancer by the vaginal smear", but he did not manage to convince his colleagues, who even called him the "Greek Storyteller" behind his back! It was in that year that the researcher turned his attention to hormonal cytology and sexual physiology, causing new achievements in Endocrinology.

In the meantime, a period of intensive research was launched by G. Papanicolaou and his associates Herbert Traut (Pathologist), Andrew Marchetti (Gynaecologist) and Japanese illustrator Murayama. The couple did not keep regular working hours; they also worked at the weekends, because they had to look after the experimental animals as well. Some said that the Pap smear test was a product of luck. The majority, however, agree with Pasteur's view that 'luck favours only the prepared mind'. His persistence, patience and dedication to make his dream come true led G. Papanicolaou to scientific glory.

Years went by fast, pleasantly and productively. The Papanicolaou's followed the same routine every day: they left their Long Island home for New York every morning at seven-thirty, Andromache behind the wheel and the doctor reading his notes or papers or listen to classical music. Not in the passenger seat but, always, seated at theback. In 1941 Papanicolaou's research efforts seemed to be more widely recognised. The publication of his paper titled "New Cancer Diagnosis - Diagnosis of Uterine Cancer by the Vaginal Smear" was received with great interest and soon followed by another paper titled: 'The Diagnostic Value of Vaginal Smear in Cervical Cancer', a landmark publication in the history of Medical Science. Until Pap test establishment, the diagnosis of cervical cancer was made only in women when the tumor had already formed and was by biopsy. In 1945 his studies were placed under the auspices of the American Cancer Society. A new scientific field, Exfoliative Cytology, had been born ("my baby" as G. Papanicolaou used to say).

Dr Pap worked at Cornell University until 1961 obtaining all the titles of the academic hierarchy. He launched intensive training courses for physicians and laboratory technicians, some of them, trained by him himself, were the pioneers of Cytopathology in Greece. He continued his research with the same zeal studying not only vaginal smear cells but also other material from the stomach, the bronchi, the cerebrospinal fluid, ascetic and pleural fluid and so on. He was the first that introduced the term "dyskaryosis" (Greek origin "dys"= abnormal, "karyo" = nucleus) in order to describe the abnormal morphology of cells in premalignant changes of uterine cervix.

In 1948, the 1st National Cytology Conference was held in Boston (American Cancer Society), while in Germany, George Papanicolaou was proclaimed to be the 'Father of Modern Endocrinology', acknowledging all the 12 years of his life and the 32 of his papers dedicated to women's hormonal phases; his results had become the starting point for diagnosing and treating menstrual cycle disorders and fertility problems. He, who refused to have children, became the cause of many children being born thanks to his research.



EFCS NEWSLETTER

ISSUE 2/2021



EFCS
European Federation of
Cytology Societies

In 1954, at the pinnacle of his scientific activity, he published the crowning jewel to his research activity, the “Atlas to Exfoliative Cytology”. He used to say “This is one of my final contributions to Science. I thanked the Lord for giving me a long – live and the strength to bring this work to a happy end”.

The first time the nominator who supported G. Papanicolaou for the Nobel Prize died shortly before the award ceremony. G. Papanicolaou accepted the committee decision and continued his indefatigable work. The second time, it was unfortunately, the scientist himself who died, shortly before the final vote for the prize, and the Nobel is not given posthumously. He received plethora of honorary distinctions and awards as the Lasker award, the highest American scientific distinction. At the hospital where he had worked for almost 50 years there is a statue of the great Greek Researcher, the Anatomy Library bears his name, beneath which Cornell Medical graduates take their oath. Unesco (2012) together with Hellenic Society Clinical Cytology honoured his memory with events around the world.

He too was a man, with his own fears (he was afraid of airplanes), loves and weaknesses: He smoked and only quit the habit in the final years of his life. He enjoyed choice food and kept a cellar of rare wines. He liked fine clothes and was stylishly dressed. In his leisure time he enjoyed playing cards (bridge, poker and pinnacle). He loved swimming but above all, however, he loved music. At home he spent his time at his microscope listening to classical music, occasionally indulging in a duet with Andromache at the piano, and he never missed an opportunity to attend a concert at the New York Metropolitan Opera. Regarding music he once wrote: “The Violin repaired my soul; it gave me strength to withstand my desperate isolation and raised some of my ideals”, and “I could not have led such a harsh life without the counterbalance of music”. It was in February 19, 1962 when 79 years old Dr.Pap passed away from heart attack without having the chance to see in operation the new Institute of Anticancer Research in Miami and left behind for ever his microscope and study of cancer cells. Besides, only death could stop his research activity with the incredible hard work and persistence.

Today, 59 years after his death, the extent and recognition of this cytological method is well known to all of us. The Pap test is a standard, routine examination. Early detection of cancer, whether of the genitalia or other organs, such as the bladder, the lung or the breast, often means full recovery and can hopefully shift statistical data from death cases to increased survivors’ numbers. Prevention and early treatment can virtually bring recovery to 100%. The molecular testing in cytological material is nothing but an extension of G. Papanicolaou’s basic idea : early detection of cancer in cytological material. G. Papanicolaou’s philosophy does not change. One type of test does not change the history of Cytology. With the development of Molecular Biology, Cytology overcomes its initial simple clinical application and enters in prognosis and prediction, thus contributing to the modification of diagnostic - therapeutic protocols (precision medicine).

Thousands of patients pay tribute and express their gratitude along with us today. George Papanicolaou’s magnificent work and his wife’s invaluable contribution are the best example and precious heritage for those of us now working in the scientific or other fields. In the entire world George Papanicolaou remains a symbol. After his death he passed into immortality and he will be remembered forever as younger generations learn about him.

Maria Nasioutziki MD PhD MIAC
General Secretary of Hellenic Society of Clinical Cytology



EFCS
European Federation of
Cytology Societies

Thank you for your time!

Please send your feedback to residentsyoung@efcs.eu



EFCS
European Federation of
Cytology Societies

The EFCS Newsletter



Expected Release Date of
Next Issue:
June 2021