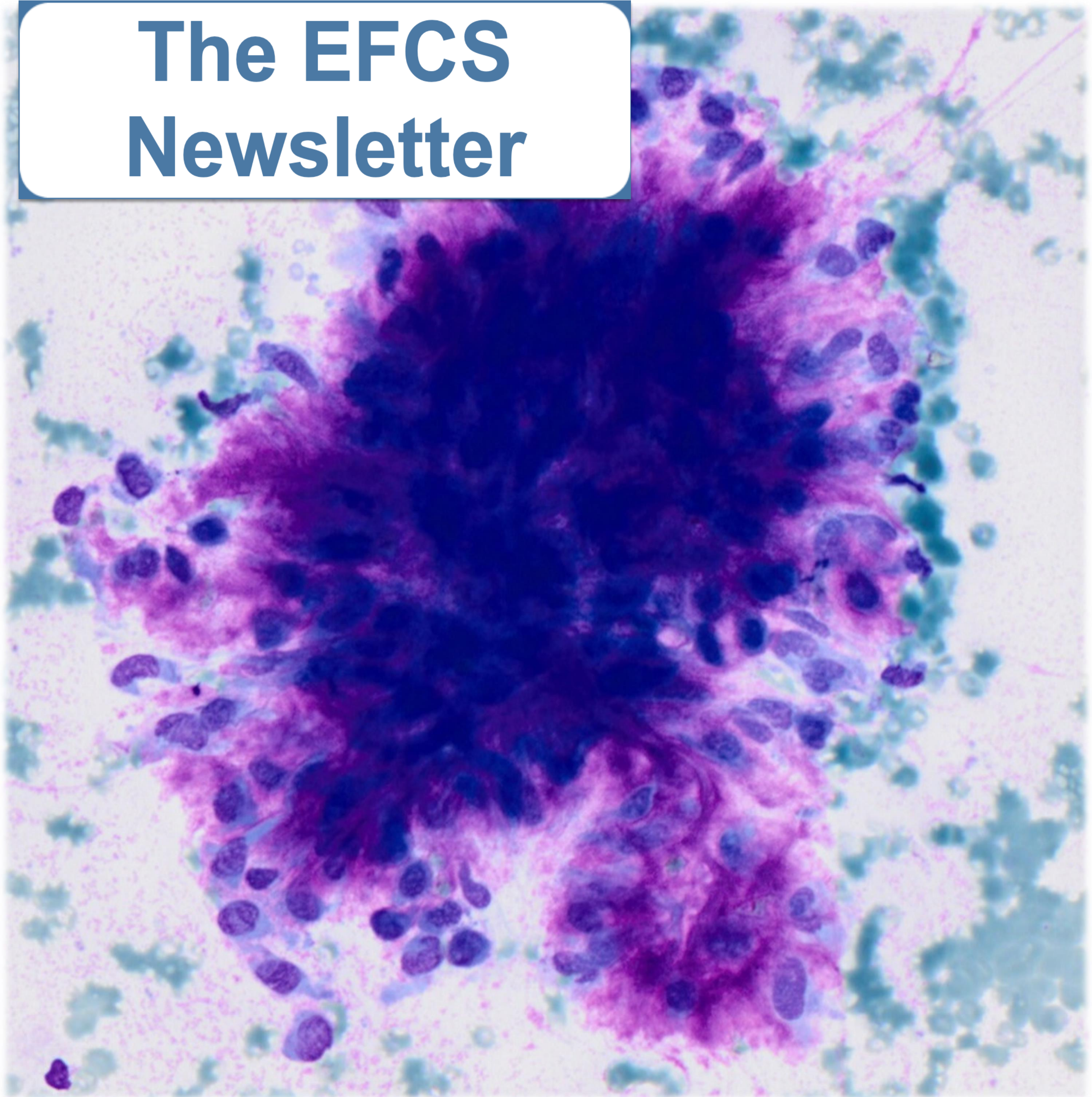




EFCS
European Federation of
Cytology Societies

The EFCS Newsletter



Issue 2-3/2023



EFCS NEWSLETTER

ISSUE 2-3/2023



EFCS
European Federation of
Cytology Societies

Dear Friends and Colleagues,

After a year break, the European Congress of Cytology is returning in great style! I hope next month all of us can meet in Budapest. For the Young EFCS Committee it will be a very exciting event. We are preparing a session about mentoring and sponsoring in cytopathology. This will be one of the Melting Point sessions. Besides the Young EFCS Committee members (Christina Kåbjörn-Gustafsson, Despina Argyropoulou, Istvan Kovacs and me) we invited Eva M. Wojcik - a well-established cytopathologist and educator - from Loyola University Medical Center, USA. We hope that this session could help young people to find well-suited mentors and sponsors and to better understand mentor-protégé relationship. Experienced cytopathologists will also benefit from this meeting, learning about expectations young people have nowadays. We are looking forward to a fruitful discussion and we are inviting all cytopathologists to actively participate in the session. Istvan Kovacs is writing more about it in this issue of the Newsletter.

In the current issue you will also find report from another well-prepared EFCS Joint Webinar about thyroid and salivary gland cytology which took place at the end of May.

Another cytological book is going to be published soon – “Diagnostic Procedures in Patients with Neck Masses” – and thanks to their authors you can familiarize yourselves with its contents.

At the end something for all of us who like nicely illustrated cases, this time Marianne Engels presented two great thoracic pathology cases.

Summer holiday season was very quiet, that is why this is the double issue.

Enjoy reading and see you all in Budapest!

Pawel Gajdzis
Residents and YEFCS Committee



EFCS NEWSLETTER

ISSUE 2-3/2023



EFCS
European Federation of
Cytology Societies

In this issue:

- ❖ **Message from the EFCS President** (page 4)

Laszlo Vass

- ❖ **Report on the 3rd EFCS Joint Webinar on Thyroid and Salivary Gland Cytology** (page 5)

Ivana Kholová

- ❖ **Join us in Budapest at the YEFCS Melting Point Session!** (page 9)

Istvan Kovacs

- ❖ **Announcement of publication of “Diagnostic Procedures in Patients with Neck Masses” by Springer in 2024** (page 14)

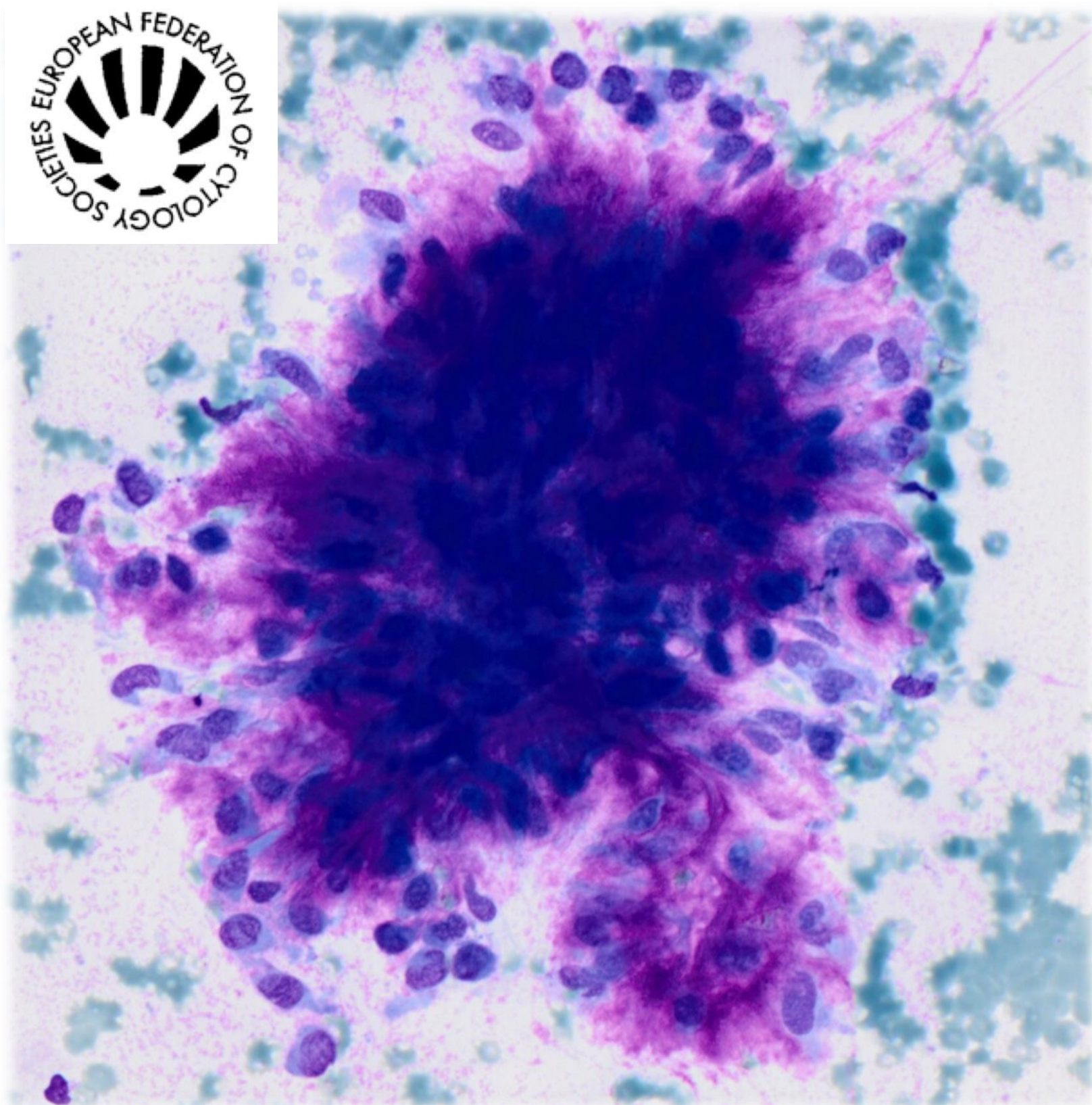
Jerzy Klijanienko

- ❖ **Case challenges!** (page 18)

Marianne Engels

- ❖ **Trivial facts of cytopathology** (page 28)

Despina Argyropoulou



Cover photo:
Pleomorphic adenoma
(MGG)



EFCS NEWSLETTER

ISSUE 2-3/2023



EFCS
European Federation of
Cytology Societies

Message from the EFCS President

“Health viewed is the beauty itself! Cytopathology in all its aspects recognizes, fights against disharmony, irregularity and diseases which have always been present in life, especially in our 21st century world.” I started up my last message with the above thoughts. Now and here I am convinced more than ever that the above words are still valid and important. I am thankful to all the responsible Leaders, Board Members of our Society, moreover to everyone who has already got involved or will be active part in making this Congress happen! Our original opinion was that all the participants may become personally productive part of the scientific event, may add smaller or wider additional values to the expected final hopefully historical result.

As of today, we already have 13 organized Melting Point sessions, as backbone of the event. There will be 14 exclusively digital slide seminars, min. 4 Plenary Sessions, 13 Companion Meetings partially National or organization based, IAC and QUATE examinations and the key event: the lecture of Prof. Fernando Schmitt. Taking advantage of the Congress itself, a Semmelweis University based post congress day is also under construction dealing with the situation, importance of teaching, experiencing cytopathology as important part of medical studies both at undergraduate and graduate level. This is planned at the [Department of Pathology and Experimental Cancer Research](#), SEMMELWEIS UNIVERSITY, FACULTY OF MEDICINE. Our host will be Prof. Dr. András MATOLCSY.

“Our legislators and those that write the laws of our societies have their way with words. They often do not have the scientific understanding of how the very essence of life works. The biologist on the other hand shies away from the intricacies of legal jargon fascinated by the science. Since the fabric of society is made up of people (of all sorts) and the cell (of all sorts) is the fabric of people, there is room for cross discipline learning to create a better society.” (Ashley Davidoff MD, radiologist, Boston Medical Center) We may focus on how biology of the cell may be inferred in the workings of our society.

Let us follow the wise way of the nature as this has brought us together as Fellows of Cytology and the result of our work is for everybody and general.

Laszlo Vass
EFCS President



Report on the 3rd EFCS Joint Webinar on Thyroid and Salivary Gland Cytology, 31st May 2023

The 31st May was a true festival for all European cytology lovers with participants from countries outside Europe too! More than 600 participants joined in the 3rd EFCS webinar for two talks and four case presentations on Head and Neck Cytology. The webinar was organized by The British Association for Cytopathology and Finnish Society of Clinical Cytology. The organizing team members were Danijela Vrdoljak-Mozetic, Ashish Chandra and Ivana Kholová. The scientific Committee comprised two UK representatives: Ashish Chandra and David Poller and two Finnish representatives: Ivana Kholová and Jussi Tarkkanen.

The first talk by David Poller elegantly covered the 3rd Edition of The Bethesda System for Reporting Thyroid Cytopathology, to be published in July-September 2023. The discussion also described the British 'Thy' terminology system and the Italian 'TIR' terminology. Ivana Kholová then gave a detailed talk on the role of cell blocks in salivary gland diagnostics. The following discussion included nice case examples with the description of relevant ancillary techniques for salivary gland cytology.

Two clinical case presentations then covered thyroid lesions and two described salivary gland entities. The UK presenters were Josephine Wright and Shonali Natsu both of whom presented challenging and rare thyroid tumors. Finnish colleagues Jetta Kelppe and Eliisa Viljanen showed salivary gland pearls: nodular fasciitis and sebaceous lymphadenoma.

In addition to the educational aspects, we as speakers and lecturers also had a great time. There was time for mention of British cultural institutions such as the late Her Majesty the Queen, English 'gentlemen', fish and chips, and British football. Saunas on lake shores, arctic forests, polar days and nights with the Aurora Borealis are famous pastimes in Finland.

Yes, cytology is rocking! It was a great three hours of cytology education, beauty of cells and cytology community friendship.

The webinar is available on EFCS website.

Ivana Kholová

President of Finnish Society of Clinical Cytology

Chair of EFCS Scientific Committee

(continues on the next page)

Report on the 3rd EFCS Joint Webinar on Thyroid and Salivary Gland Cytology, 31st May 2023

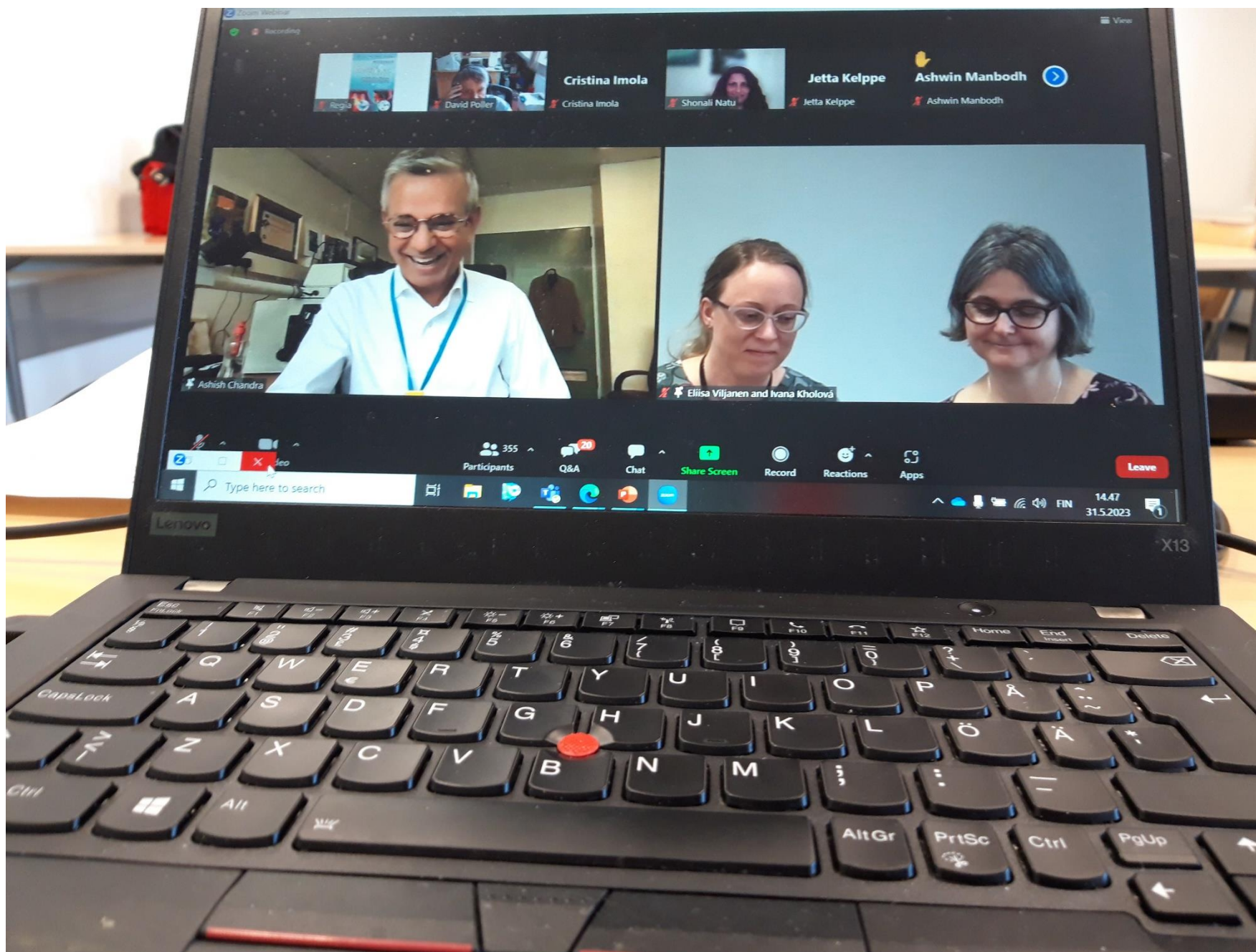


Figure 1: On zoom stage Dr Ashish Chandra in London and Dr Eliisa Viljanen and Dr Ivana Kholová in Tampere.

Figure 2: Dr Josephine Wright and Dr Ashish Chandra enjoying seminar in Guy's and St Thomas' Hospital, London, UK.



(continues on the next page)

Report on the 3rd EFCS Joint Webinar on Thyroid and Salivary Gland Cytology, 31st May 2023



Figure 3: Office window view of Dr Josephine Wright and Dr Ashish Chandra during seminar.

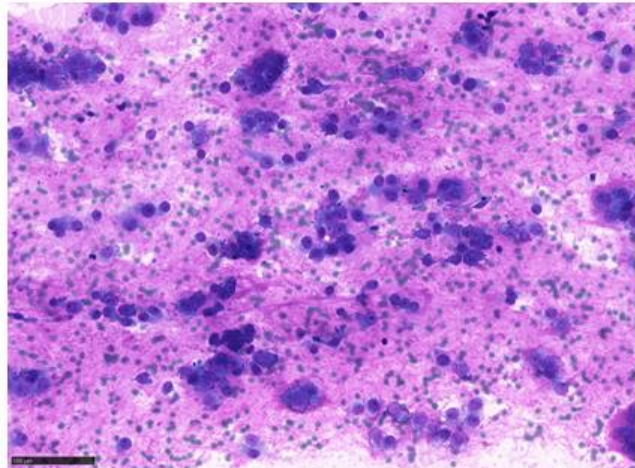
Figure 4: Dr Eliisa Viljanen and Dr Ivana Kholová enjoying seminar at Tampere University Arvo building in Tampere.



Figure 5: Office window view of Dr Eliisa Viljanen and Dr Ivana Kholová during seminar.

(continues on the next page)

Report on the 3rd EFCS Joint Webinar on Thyroid and Salivary Gland Cytology, 31st May 2023



Take Home Messages: NUT-rearranged carcinoma (NSD3::NUTM1)

- Differential diagnosis includes:
 - Papillary thyroid carcinoma
 - Anaplastic or undifferentiated thyroid carcinoma
 - Matrix producing neoplasm – primary intrathyroidal adenocarcinoma ex pleomorphic adenoma
- Thyroid NUT carcinoma is different
 - Morphology is variable in both cytological and histological assessment
- Immunohistochemistry
 - Consider a lower NUT IHC threshold >50%
- Molecular
 - Role of broader NGS panels to include NUTM1 fusions



Figure 6: Thyroid case of NUT carcinoma was presented by Dr Josephine Wright from Guy's and St Thomas' Hospital, London, UK.

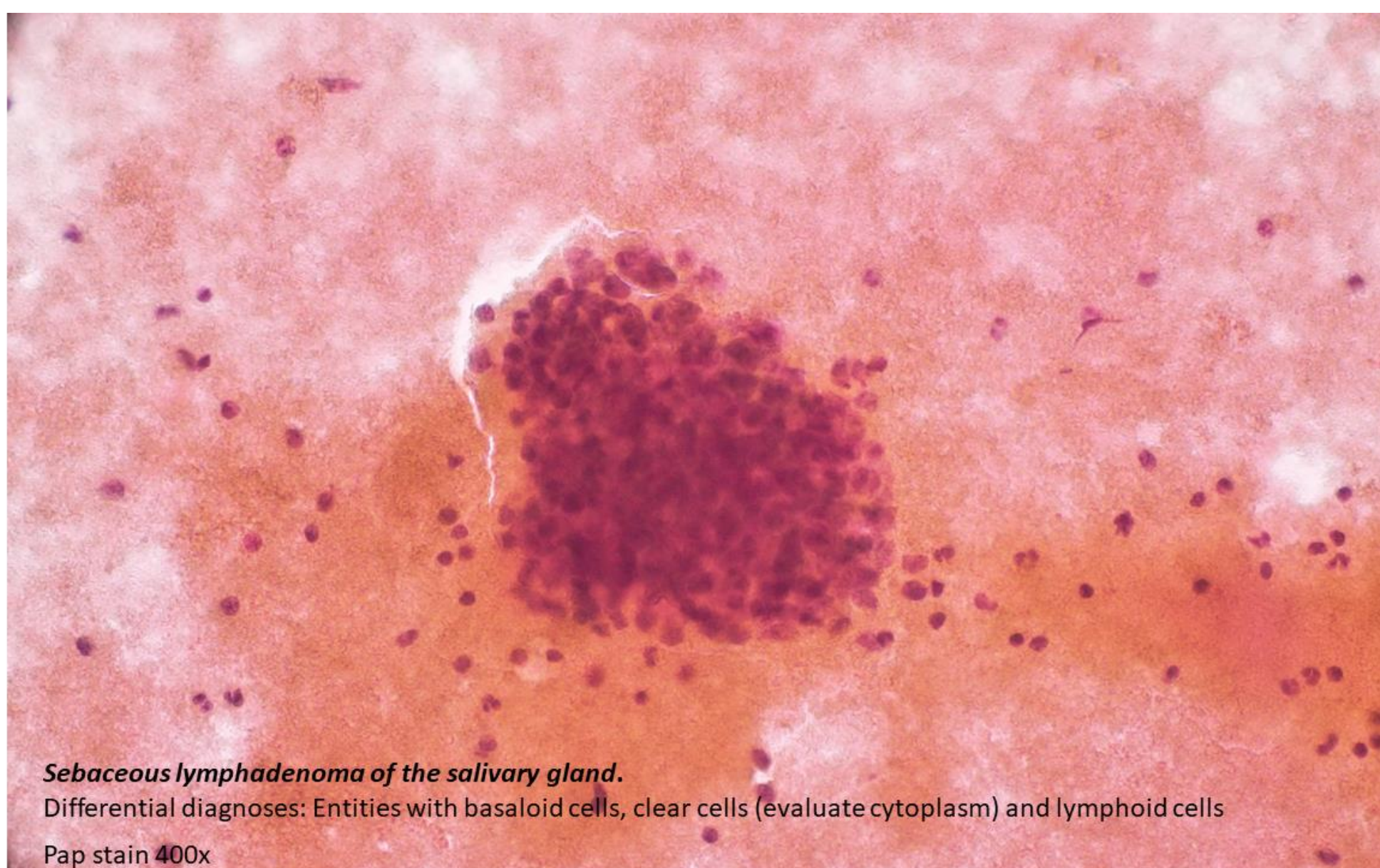


Figure 7: Case of salivary gland sebaceous lymphadenoma was presented by Viljanen from Tampere University and Fimlab Laboratories, Tampere, Finland.

Dr Eliisa



Join us in Budapest at the YEFCS Melting Point Session!

In our empirical profession, communication is of great importance, both with our patients and with each other. In line with this, the 44th European Congress of Cytology in Budapest, departing from the usual congress structure, encourages all its speakers and participants to engage in a discourse. There will be Melting Point (MP) Sessions, on topics covering the nomenclature, science and diagnostics of cytology, provoking the expression of the views of eminent representatives, a session will be dedicated to the conflict of the generations.

We started a dialogue on this topic in Baltimore at the joint IAC-ASC Congress last November, when Pawel Gajdzis and I were given the question by congress president Dr Laszlo Vass - what are the realities and dreams of the young cortex?

Clearly, it would be impossible to express all our personal realities and emotions about how we came to the decision and how we get along in the world of cytology but I think we all have good experiences, frustrations and criticisms worth speaking up for, and this will be a great opportunity to do so!

With the commitment from our representative mentors Eva Wojcik, Christina Kabjorn Gustafsson, and protegees and YEFCS members Despina Argyropoulou, Pawel and myself we plan to organize a panel discussion on mentorship and sponsorship. At first, we had vague and different ideas on either or both concepts. Who is a mentor and protege? Or a sponsor and mentee? This immediate variability gave us the hope that beyond the level of nomenclature this conflict would just get deeper, providing fertile ground to an argument. We wish to start a dialogue on how we were affected by engaging with important mentor figures in our professional life and what qualities and what kind of communication we expect from the perspective of our own generation. I am particularly looking towards a debate on common challenges like online communication. Though it could be interesting to argue on stage, I would heartily invite you to join us at the congress, preferably live, and engage in the argument!

As a warm-up, there will be a questionnaire on mentoring and sponsorship that we would like to encourage you to fill in and share your thoughts with us. The questionnaire will be available in advance and on-site at the congress as well. We will gather and present results of all received answers at the MP Session, furthermore release an on-site voting on additional, multiple choice questions that reflect on main topics that we will discuss.

(continues on the next page)

Join us in Budapest at the YEFCS Melting Point Session!

Therefore we warmly expect representatives of all generations, young and old, to share your experience and thoughts so that we together can reach the melting point and adopt a new state of matter! (Yold? Oloung?)

In addition, as all MP Sessions, a corresponding YEFCS Slide Seminar will take place focusing on exciting case presentations in the name of cooperation between generations.

But anyway, have you heard of the YEFCS? This could be a good time to get to know it, as we plan to organize a more casual congress programme dedicated to the young generation on-site!

But if you don't feel like joining this particular session, there will be debates all over the congress that will be worth listening to and getting involved in!

Thank you for reading this and hopefully see you all there!

Istvan Kovacs,
Young EFCS Committee



MP 11 YEFCS- A PANEL DISCUSSION BETWEEN THE GENERATIONS ON MENTORSHIP AND SPONSORSHIP

📍 Plenary 📅 3 October 2023 ⌚ 17:30 - 19:00

"Realities, and dreams of the young cortex" –

A Panel Discussion between the generations on Mentorship and Sponsorship

Panelists:

Eva M. Wojcik, Loyola University Health System, USA:

Christina Kåbjörn Gustafsson, Ryhov Hospital Jönköping, Sweden:

Despina Argyropoulou, Hospital Garcia de Orta, Portugal

Gajdzis Pawel, Uniwersytecki Szpital Kliniczny we Wrocławiu, Poland:

István Kovács, MEDSERV Kft, Hungary.:

Join us in Budapest at the YEFCS Melting Point Session!

Dear friends and colleagues,

We would like to present to you the new scientific **EFCS project** lead by the **Young EFCS** about **mentorship and sponsorship in cytopathology**.

The idea of this project was born during our work on Young EFCS melting point session in European Congress of Cytology in Budapest.

The core group of this project is made up of the Budapest speakers: Despina Argyropoulou - Portugal, Istvan Kovacs - Hungary, Pawel Gajdzis - Poland, Christina Kåbjörn-Gustafsson - Sweden, Eva Wojcik - USA.

The core component of our project is a comprehensive survey designed to explore and analyse knowledge about mentorship and sponsorship in cytopathology among residents, young cytopathologists and experienced cytopathologists. Your valuable input will play an essential role in shaping the outcomes of this survey and will contribute to the advancement of knowledge in cytopathology training. Preliminary results will be published during the European Congress of Cytology and we also invite you to take part in the discussion of the Young EFCS Melting Point Session on the conflict of the generations!

The link to the survey is below:

<https://s.surveyplanet.com/4to3kxop>

This survey should take around 15 minutes. First question is a control question, to know that we have only pathologists as participants.

We will be grateful to you if you would accept and fill this survey.

until the end of September 2023. Everyone is welcome (age and experience don't matter).

The more participants fill the survey, the more reliable the results will be.

Please, forward this invitation to your National Society members and interested colleagues.

Thank you for your help, supporting young cytopathologists!



SEE YOU IN BUDAPEST!

The 44th EUROPEAN CONGRESS OF CYTOLOGY

Budapest, 1-4 October 2023

INVITATION

Mottos of the congress: "combined intelligence" and "melting point"
"The diagnosis by aspiration is as reliable as the combined intelligence of the clinician and pathologist makes it." (Stewart 1933).



Harmony, regularity in all instances designs at all microscopic, immunohistochemical, molecular, proteomic levels at the last end the absence of disease which we may call in morphology health. Health viewed is the beauty itself! Cytopathology in all its aspects recognizes, fights against disharmony, irregularity and diseases which have always been present in life, especially in our 21st century world. We, cytopathologists gather now in Budapest for the 44th Congress of EFCS with the hope, it will help us finding and fighting diseases for a better future.

I invite everyone interested in cytology and being aware of the above questions to come to Budapest for three days learning each other's knowledge, diverse ways of thinking. Please let us gather our arguer, disputer, controversialist brain for moving towards a healthier world. The Congress will take place from 1-4 October 2023. It is organized in a hybrid structure; however, we all will be happier and more active if being present personally. Our wish is a three days long lively, continuous personal and scientific activity in a series of traditional and non-traditional session.

The 'background' of it is the active, charming, historical, and modern city of Budapest. Let us take the challenge, please come, it will be our great privilege to see you all in Budapest!

László Vass, MD PhD, FIAC
President of the EFCS



44TH EUROPEAN

CONGRESS OF CYTOLOGY

BUDAPEST, 1-4 OCTOBER 2023

SAVE THE DATE!

XII MOLECULAR CYTOPATHOLOGY

Naples, Italy 11-12 December 2023



More info:

<https://www.molecularcytopathology.com/>

Announcement of publication of “Diagnostic Procedures in Patients with Neck Masses” by Springer in 2024

It is a great pleasure for me to announce the writing and the forthcoming publication by Springer of a book entitled: "Diagnostic Procedures in Patients with Neck Masses". This large publication will appear in early 2024. It will consist of approximately 200 pages including 44 assets (figures and tables).

The approach of this book is multidisciplinary. To achieve a complete vision, we have invited specialists from all scientific horizons to collaborate. No vision was favored. We have respected the point of view of different experts and left the field open to the expression of their opinion. This is why in this book the reader will find the elements concerning the classical histological examination, molecular biology, cytology and/or radiology.

It is obvious that there is no harmonized diagnostic protocol accepted by different specialists. This depends on different habits but also on misunderstanding of the possibilities of each technique. Not everyone knows the positive or negative effects or even the limits of technical checks. Yet, the range of possibilities is wide. The pathologist has a variety of techniques ranging from a histological biopsy, by fine needle aspiration, frozen section or molecular information. All these investigations are not "alone" but assisted by the beam of techniques and information from clinical, radiological, nuclear medicine and biology examinations.

It is obvious that we are happy that cytology plays an important role in the diagnostic process in ENT pathology. This is particularly evident in thyroid tumors, but also salivary and lymph nodes. This confirms our deep conviction of usefulness of this wonderful technique when appropriately used.

It is obvious that the diagnosis, especially in oncology, is the fruit of multidisciplinary cooperation where each specialty encounters its own difficulties and successes.

The diagnosis of cervical masses is all the more difficult, because this clinical sign can be present in different situations. Different conditions can give rise to cervical masses: it may be a metastasis of a known ENT tumor. It may be a tumor with local evolution and growth whose nature has to be characterized. Its origin may also be different: pseudotumors, carcinomas, sarcomas, lymphomas, skin tumors, salivary tumors and thyroid tumors can mimic each other.

The choice of collaborators was difficult. We have selected experts who are well recognized in their specialty and come from different universities and hospital centres. Our ambition was to create a practical book, far from purely academic canons, reporting new data and solutions in this difficult anatomical space. For these reasons, we have invited to collaborate (presented on the next pages in alphabetical order):

(continues on the next page)



Announcement of publication of “Diagnostic Procedures in Patients with Neck Masses” by Springer in 2024

- **Bayan Alzumaili**, Assistant in Head and Neck and Breast Pathology at Massachusetts General Hospital, Boston, MA, USA.
- **Barnhill Raymond**, Professor of pathology at Institut Curie, Paris, France. Founder of the North American Melanoma Pathology Study Group and International Melanoma Pathology Study Group (current president). He is a current or past member of professional societies including the WHO Melanoma Programme (defunct), EORTC, ECOG, USCAP/IAP, Cancer and Blood Vessels Research Group, Liver Metastasis Research Network, and the International Melanoma Working Group.
- **Bataille-Benoudiba Farida**, Radiologist/Hospital Practitioner Neuroradiology Department at the department of Neuroradiology at Bicetre Hospital, past General secretary of Head and Neck French Imaging from 2014 to 2020 and President of Head and Neck French Imaging since 2020.
- **Chien-Chin Chen**, President of the Taiwan Society of Clinical Cytology, Associate Professor at National Chung Hsing University (Taiwan) and Chia Nan University of Pharmacy and Science (Taiwan),
- **Cozzolina Immacolata**, Pathologist at Vanvitelli University of Naples, Italy.
- **Domanski Henryk A.**, Professor of pathology at Skåne University Hospital, Lund, Sweden. Vice-president of the Swedish Society of Clinical Cytology and a member of the European Society of Pathology, the International Academy of Cytology and the Scandinavian Sarcoma Group. President of 42nd European Congress of Cytology 2019 in Malmö, Sweden and a president of European Federation of Cytology Societies 2018-2019.
- **Kalfert David**, from the University Hospital Motol, First Faculty of Medicine, Charles University, Prague, Czechia.
- **El-Naggar Adel K.**, Professor of pathology and director of the head and neck pathology section and the subspecialty head and neck fellowship training program at MD Anderson Cancer Center, Houston, TX, USA.
- **Faquin William**, Professor of pathology at Harvard Medical School, Boston, MA, USA. Editor-in-Chief for Cancer Cytopathology, which is one of the 3 journals of the American Cancer Society.
- **Field Andrew**, Director of the Anatomical Pathology Department at St Vincent's Hospital, Sydney, Australia and Conjoint Professor at the University of New South Wales Sydney and Adjunct Professor at the Notre Dame University Medical School. President 2019 to 2022 and now Immediate Past President of the International Academy of Cytology. Co-chair of the IAC WHO IARC Cytopathology Joint Standing Editorial Board, which has led the writing and publication of the WHO Reporting Systems for Lung and Pancreaticobiliary Cytopathology in 2023. Member of the WHO Classification of Tumours Standing Editorial Board.
- **Gajdzis Paweł**, Pathologist at the Wroclaw Medical University, Poland and 4th Military Clinical Hospital in Wroclaw, Poland.
- **Kholová Ivana**, Adjunct Professor of pathology at the Tampere University, Faculty of Medicine and Health Technology, Finland. President of Finnish Society for Clinical Cytology.

(continues on the next page)

Announcement of publication of “Diagnostic Procedures in Patients with Neck Masses” by Springer in 2024

- **Klos Jan**, Pathologist Department of Pathology, Stavanger University Hospital, Norway. Member of the core group and assessor in Nordic Immunohistochemistry Quality Control since 2008, founding member of International Society of Immunohistochemistry and Molecular Morphology, international member of Australasian Immunohistochemistry Society.
- **Ko Jennifer**, Medical Director of the Cleveland Clinic Central and Enterprise Biorepositories, and of the Immune Monitoring Lab in the CITI.
- **Kowalewski Adam**, from Bydgoszcz Medical University, Poland. His research and inventions primarily focus on advancing minimally invasive diagnostics.
- **Layfield Lester J.**, Professor of pathology at Department of Pathology and Laboratory Medicine, Columbia, MO, USA. Author of major cytology publications in HN pathology.
- **Liang Sharron**, MBBS, FRCPA. Practicing cytopathologist and anatomical pathologist at St Vincent's Hospital SydPath in Sydney, Australia. She enjoys all aspects of cytopathology and has a keen interest in the growing field of molecular cytopathology. She is passionate about teaching, education and sharing new knowledge.
- **Maleki Zahra**, Associate Professor of pathology at the Johns Hopkins University School of Medicine, at the Johns Hopkins Hospital, Division of Cytopathology, Baltimore, MD, USA. Director of the Johns Hopkins Medical School Scientific Foundations of Medicine, Histology and Pathobiology course.
- **Schmitt Fernando**, Professor of Pathology at the University of Porto, Director of RISE (Clinical and Translational Research Network of the Medical Faculty) and Head of Molecular Pathology Unit at IPATIMUP, President of the International Academy of Cytology (IAC). Co-editor 3rd Ed The Bethesda System for Reporting Thyroid Cytology. Standing member of the WHO-IAC Classification of Tumours.
- **Rossi Esther Diana**, professor of pathology at Catholic University of Rome, Italy. Responsible of the task force for salivary gland lesions of the American Society of Cytopathology (ASC), co-editor of the new classification system for salivary gland Cytopathology
- **Russ Gilles**, Radiologist at La Pitié-Salpêtrière Hospital and Centre de Pathologie et d'Imagerie, Paris, France. Expert in thyroid diagnostic and interventional imaging. Leader in developing the European-Thyroid Imaging and Reporting Data System (EU-TIRADS). Member of the European Thyroid Association and US Board and American Thyroid Association. Faculty member of the French US Imaging Diploma and the Hungarian Papillon US Course.
- **Sewell William**, Immunopathologist, St Vincent's Hospital Sydney. Conjoint Associate Professor, School of Clinical Medicine, University of New South Wales Sydney, Australia.
- **Souza da Silva Ricella M.**, Assistant pathologist and preceptor at the Federal University of Paraíba, Brazil and Research Trainee in Molecular Pathology at IPATIMUP. Professor of Pathology at the Faculty of Medicine of the Federal University of Paraíba, and official forensic doctor in the State of Paraíba, Brazil.

(continues on the next page)

Announcement of publication of “Diagnostic Procedures in Patients with Neck Masses” by Springer in 2024

- Theocharis Stamatis**, Professor of Pathology at National and Kapodistrian University of Athens, Greece. His research interests include, among others, biomarkers in pathology and cytopathology, molecular pathology and toxicology.
- Tissot Hubert**, Nuclear medicine physician at Institut Curie, Paris, France. His areas of interest include molecular imaging of ENT tumors, radioligand therapy and molecular imaging of prostate cancer.
- Versa Ostojic Damjana**, Clinical cytopathologist at Clinical Hospital Centre Rijeka, Croatia.
- Vielh Philippe**, Professor of pathology at Medipath and American Hospital of Paris, France. Former President of the French Society of Cytology (SFCC), President of the 31st European Congress of Cytology in 2005 (Paris, France) and Secretary General of the European Federation of Cytology Societies (EFCS) for 7 years (2005-2012). He chaired the 18th International Congress of Cytology in Paris (2013), and was President of the International Academy of Cytology (IAC) for 3 years (2013-2016). Chair of the European Society of Pathology (ESP) Cytopathology Working Group since 2018.
- Vrdoljak-Mozetic Danijela**, Assistant Professor at Faculty of medicine University of Rijeka, Croatia. Past president of Croatian Society for Clinical cytology. Secretary General of European Federation of Cytology Societies since 2021.
- Zeppa Pio**, Professor of pathology at the University of Salerno, Italy and Chief of the Pathology Institute. Former secretary of the Working Group (WG) of European Society of Pathology (ESP).

Here we would like to thank all these experts. We hope that this book will harmonize the understanding of all these described techniques and define the role of each diagnostic option. We wish you a good read and invite you to discuss it at the various meetings of medical sciences.

With kind regards,

Jerzy Klijanienko, surgical pathologist, professor and senior consultant at the Institut Curie, Paris, France, Past president of EFCS and presently Vice-president of the Société Française de Cytologie Clinique.

Olivier Choussy, surgeon, Head of the Department of Head and Neck Surgery at the Institut Curie in Paris (France),

Beatrix Cochand-Priollet, surgical pathologist, Past General Secretary of EFCS, Past President of the Société Française de Cytologie Clinique, actually Associate Professor at the department of Pathology, Hopital Cochin AP-HP Centre, Université Paris-Cité, Paris (France), and Editor-in chief EFCS Eurocytology website

Wojciech Golusiński, surgeon, Professor, Head of the Department of Head and Neck Surgery and Oncological Laryngology at the University of Medical Sciences in Poznan (Poland) and President of the European Head and Neck Society.



Case Challenges!

Case Challenges!

1

Female patient, 71 years, TBNA lymph node 7.

History: Breast carcinoma confirmed several years ago, now enlarged mediastinal and hilar lymph nodes. Bronchoscopy and TBNA from lymph node 7 to exclude pulmonary metastasis, dd lung carcinoma.

Fig. 1. May-Grünwald-Giemsa stain (MGG),
obj. x40

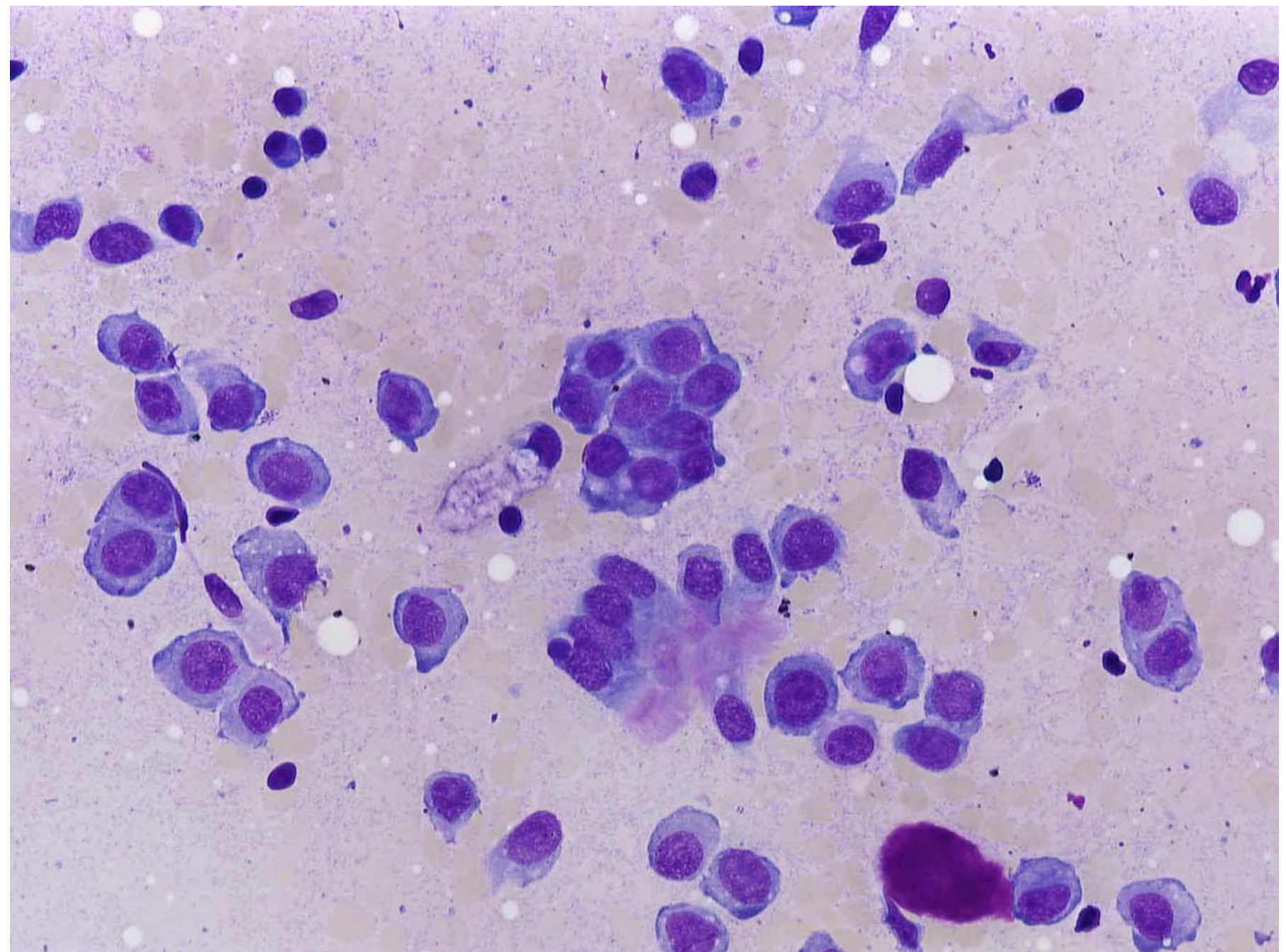
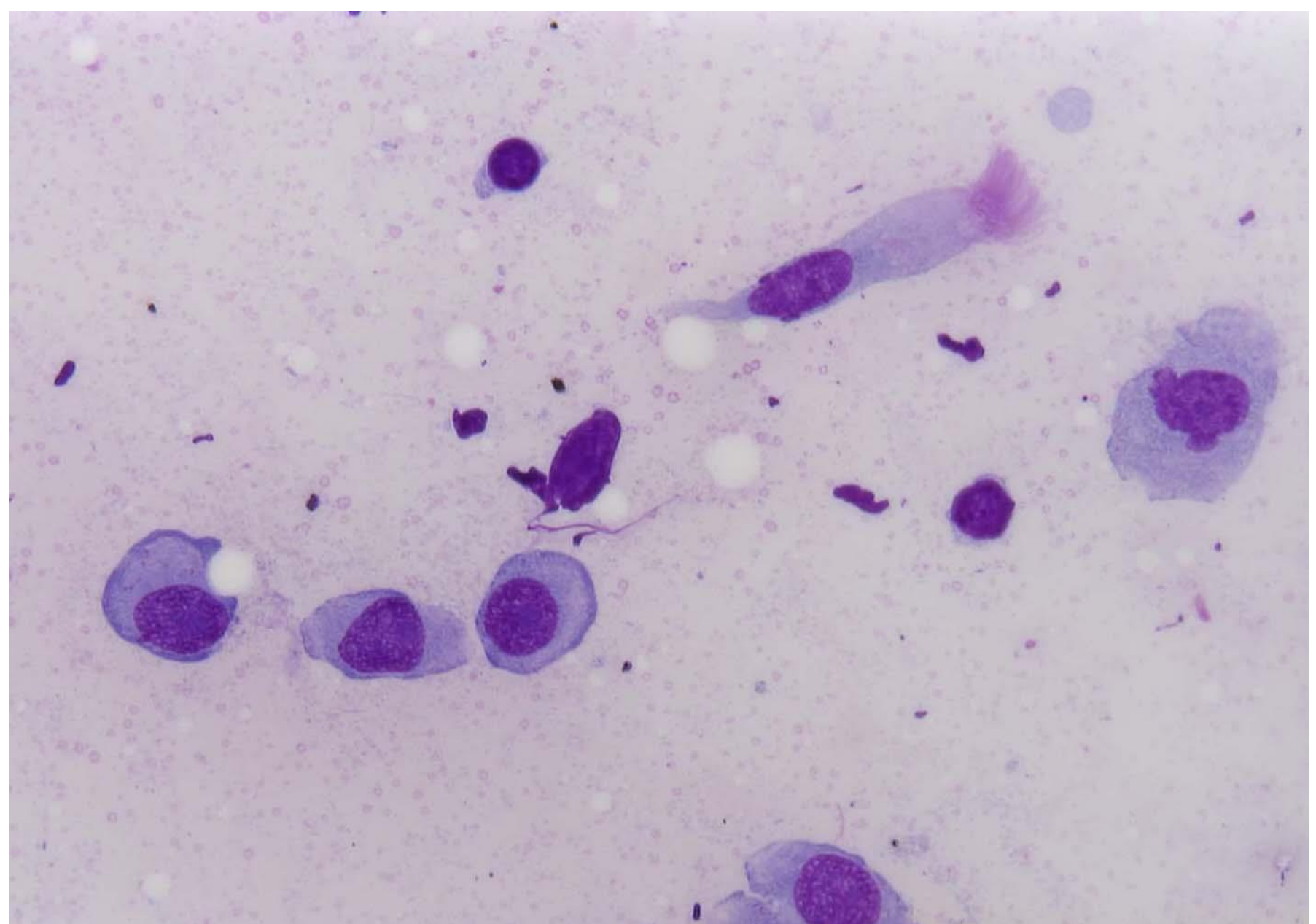


Fig. 2. May-Grünwald-Giemsa stain (MGG),
obj. x63



Case Challenges!

1

**Fig. 3. May-Grünwald-Giemsa stain (MGG),
obj. x63**

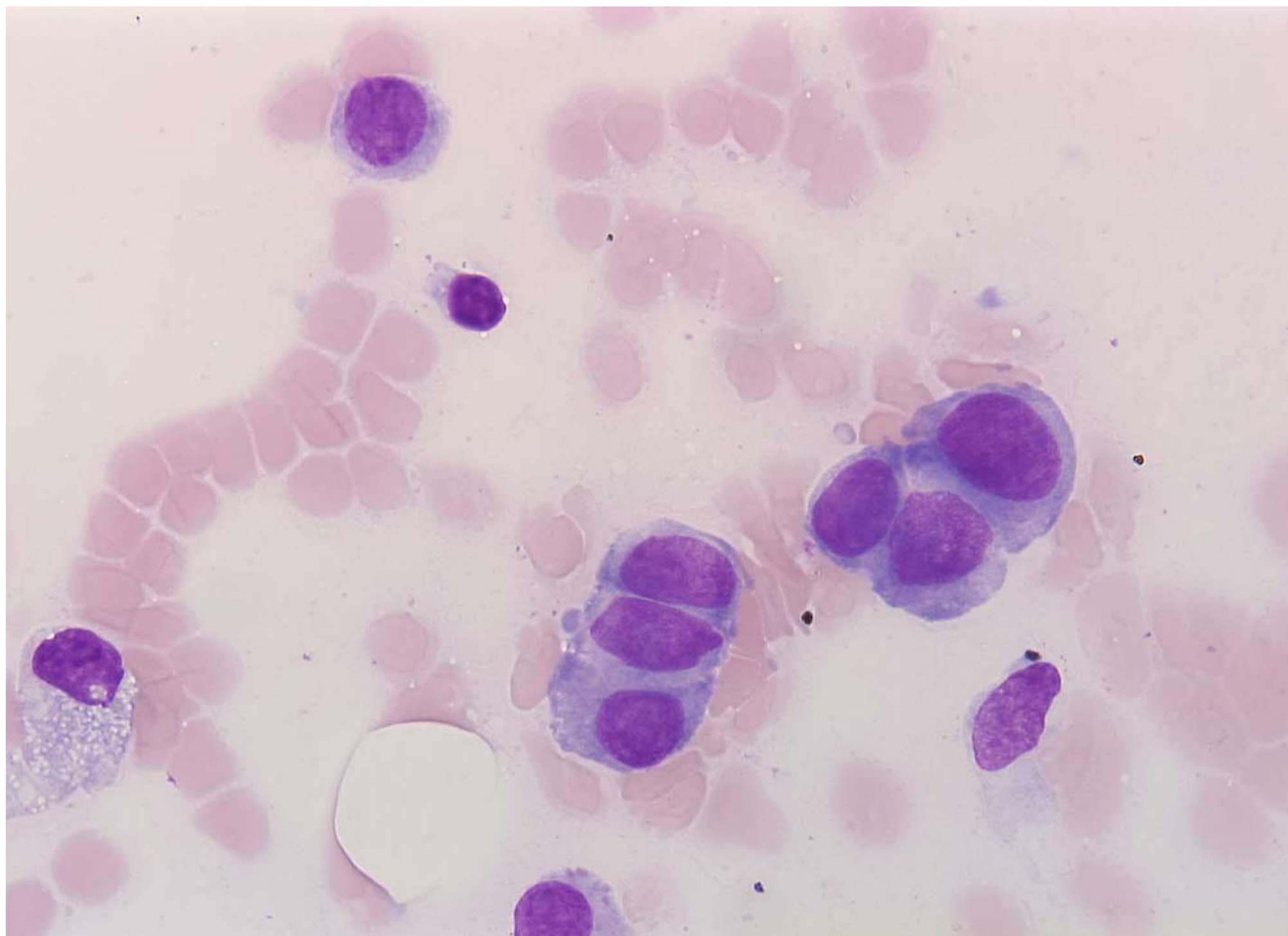
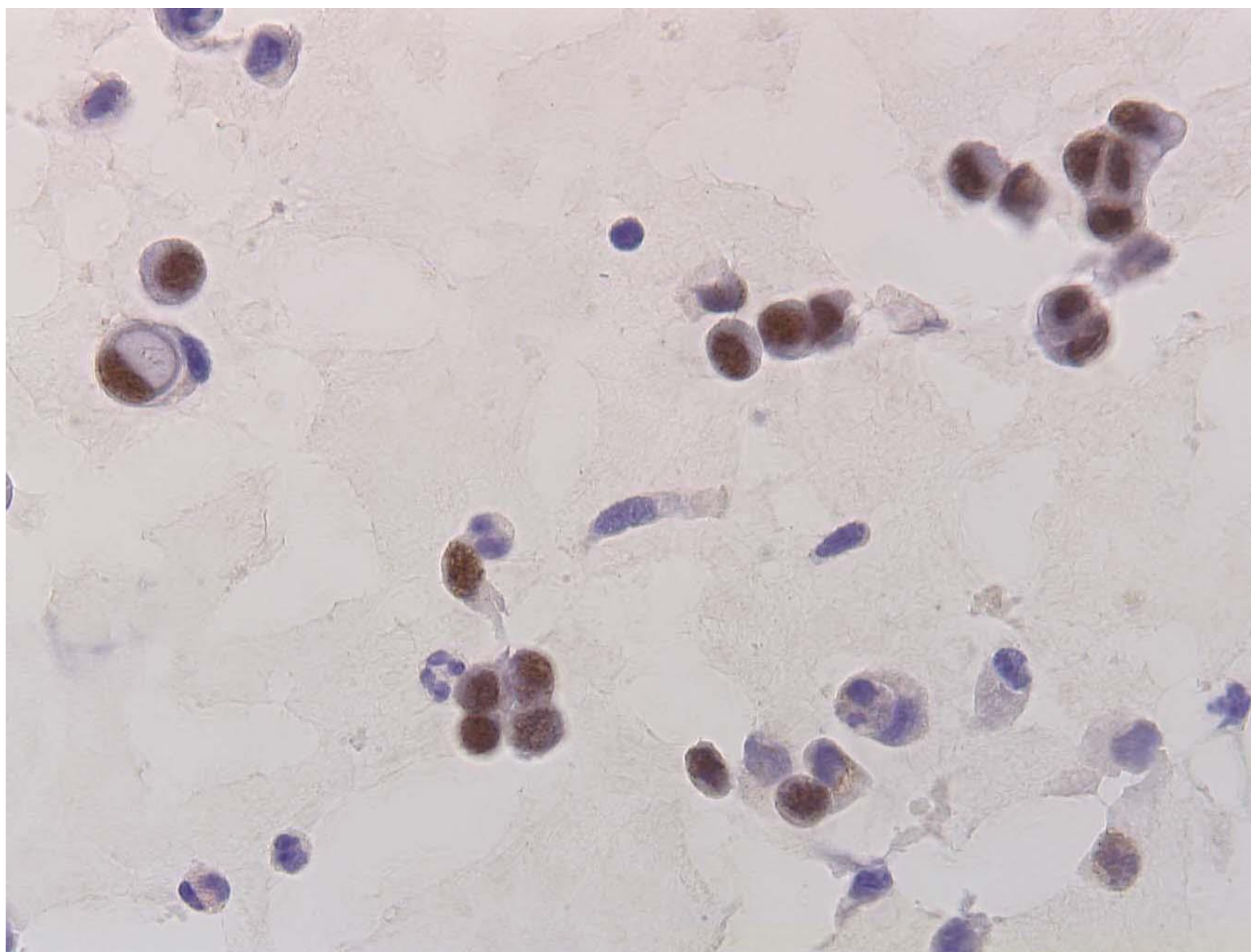


Fig. 4. GATA3, obj. x63





Case Challenges!

1

Female patient, 71 years, TBNA lymph node 7.

History: Breast carcinoma confirmed several years ago, now enlarged mediastinal and hilar lymph nodes. Bronchoscopy and TBNA from lymph node 7 to exclude pulmonary metastasis, dd lung carcinoma.

QUESTIONS

- a) Describe what you see.
- b) What does it represent?
- c) What is its significance?

Case Challenges!

- 1** Female patient, 71 years, TBNA lymph node 7.
- History:** Breast carcinoma confirmed several years ago, now enlarged mediastinal and hilar lymph nodes. Bronchoscopy and TBNA from lymph node 7 to exclude pulmonary metastasis, dd lung carcinoma.

ANSWERS

- a) Cellular smears with some lymphocytes and blood in the background. A few normal ciliated respiratory epithelial cells. Several atypical cells with medium-sized, polygonal cytoplasm and slightly enlarged nuclei, smooth nuclear contour and bland chromatin pattern. A small nucleolus is visible in some of the cells. They are arranged as single cells or in small flat sheets. The atypical cells are positive for GATA3.
- b) Lymph node metastasis of a GATA3 positive tumor, consistent with metastasis of breast carcinoma.
- c) Without immunochemistry the atypical cells might be misdiagnosed as benign respiratory epithelium with reactive changes. Reactivity for GATA3 is a proof for an extrapulmonary origin of these cells and a strong argument for metastatic disease by breast carcinoma.

Final diagnosis: Metastatic disease of breast carcinoma with involvement of lymph node 7 (subcarinal).

Comment: Pulmonary metastasis is occurring three times as often as lung cancer. The bland cytomorphology of the atypical cells in this case is found quite frequently in metastatic disease of breast carcinoma. So, if there is a history of breast carcinoma, the threshold to apply immunochemistry should be low.

Author of the case:

Marianne Engels

Chair of EFCS Educational Committee

EFCS president-elect

References:

Baloch ZW, Geisinger KR. Pulmonary and thoracic metastases. In: International Academy of Cytology – International Agency for Research on Cancer – World Health Organization Joint Editorial Board. WHO Reporting System for Lung Cytopathology. Lyon (France): International Agency for Research on Cancer; 2022. (IAC-IARC-WHO cytopathology reporting systems series, 1st ed.; vol. 1)

Nambirajan A, Longchar M, Madan K, Mallick SR, Kakkar A, Mathur S, Jain D. Endobronchial ultrasound-guided transbronchial needle aspiration cytology in patients with known or suspected extra-pulmonary malignancies: A cytopathology-based study. *Cytopathology*. 2019 Jan;30(1):82-90. doi: 10.1111/cyt.12656. Epub 2018 Dec 21. PMID: 30444548.

Case Challenges!

2

Male patient, 47 years, pleural effusion.

History of malignant melanoma, primary manifestation as a tumor of the abdominal wall, primary diagnosis two years ago. Now pleural effusion.

Fig. 1. May-Grünwald-Giemsa stain (MGG),
obj. x40

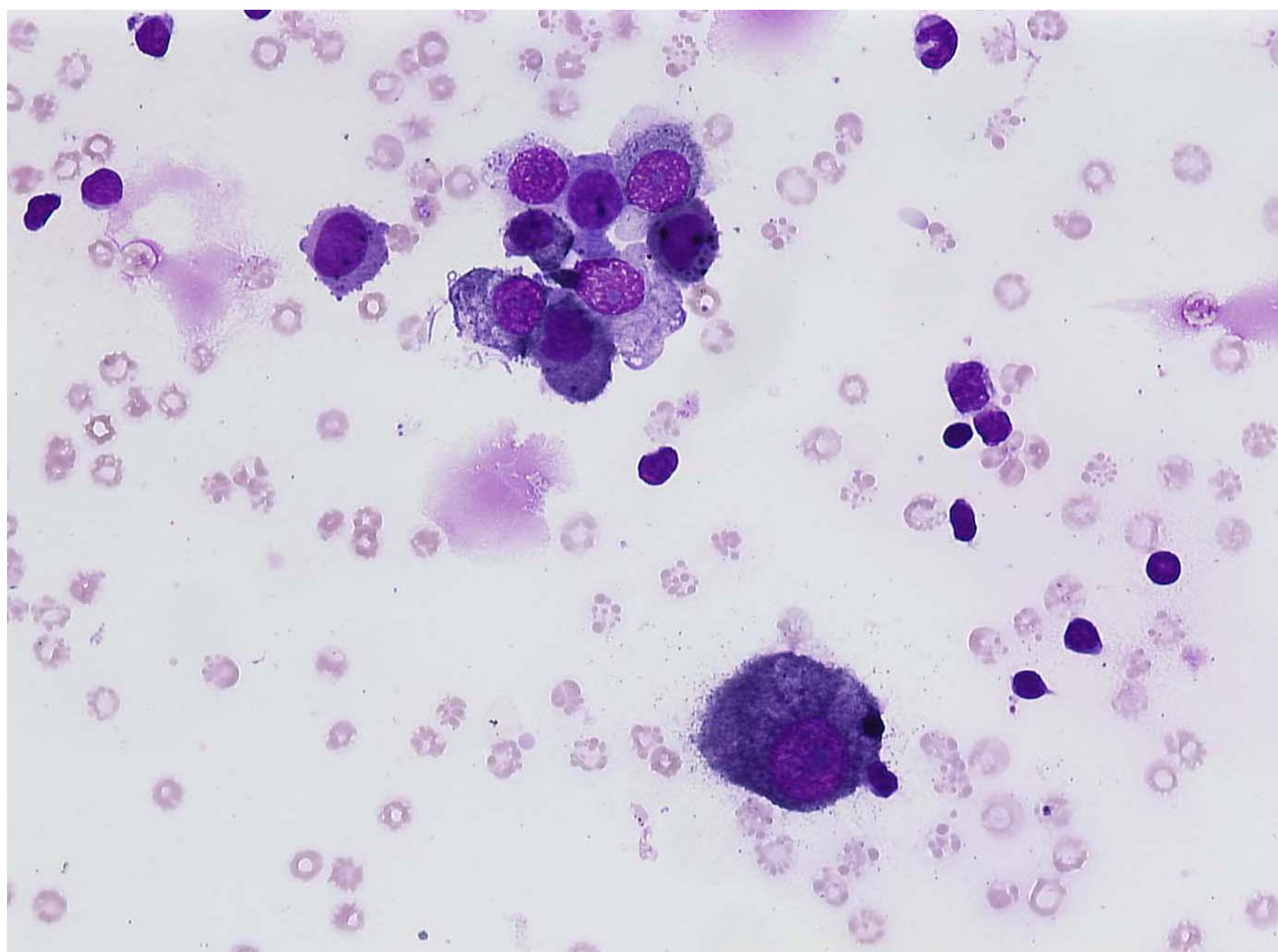
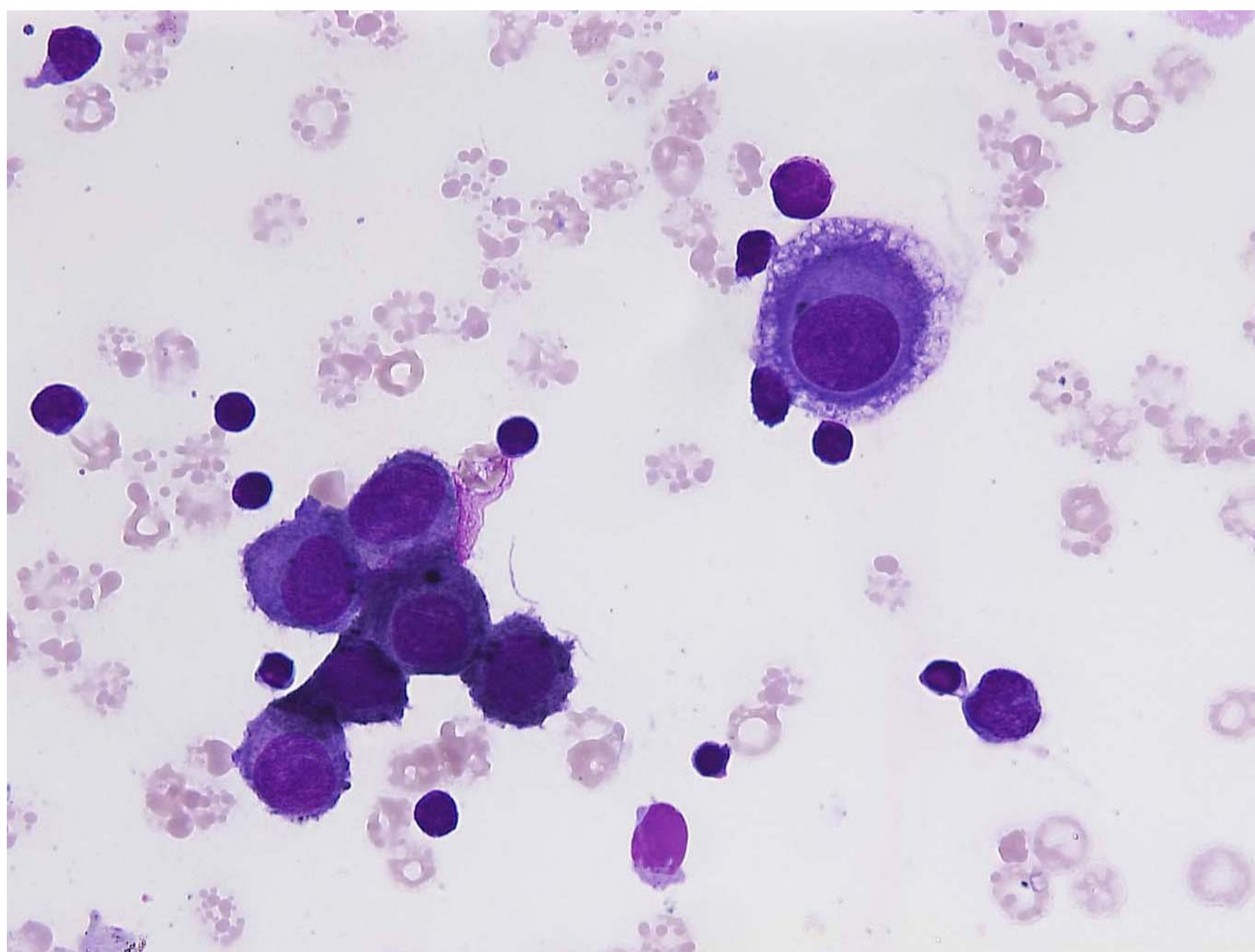


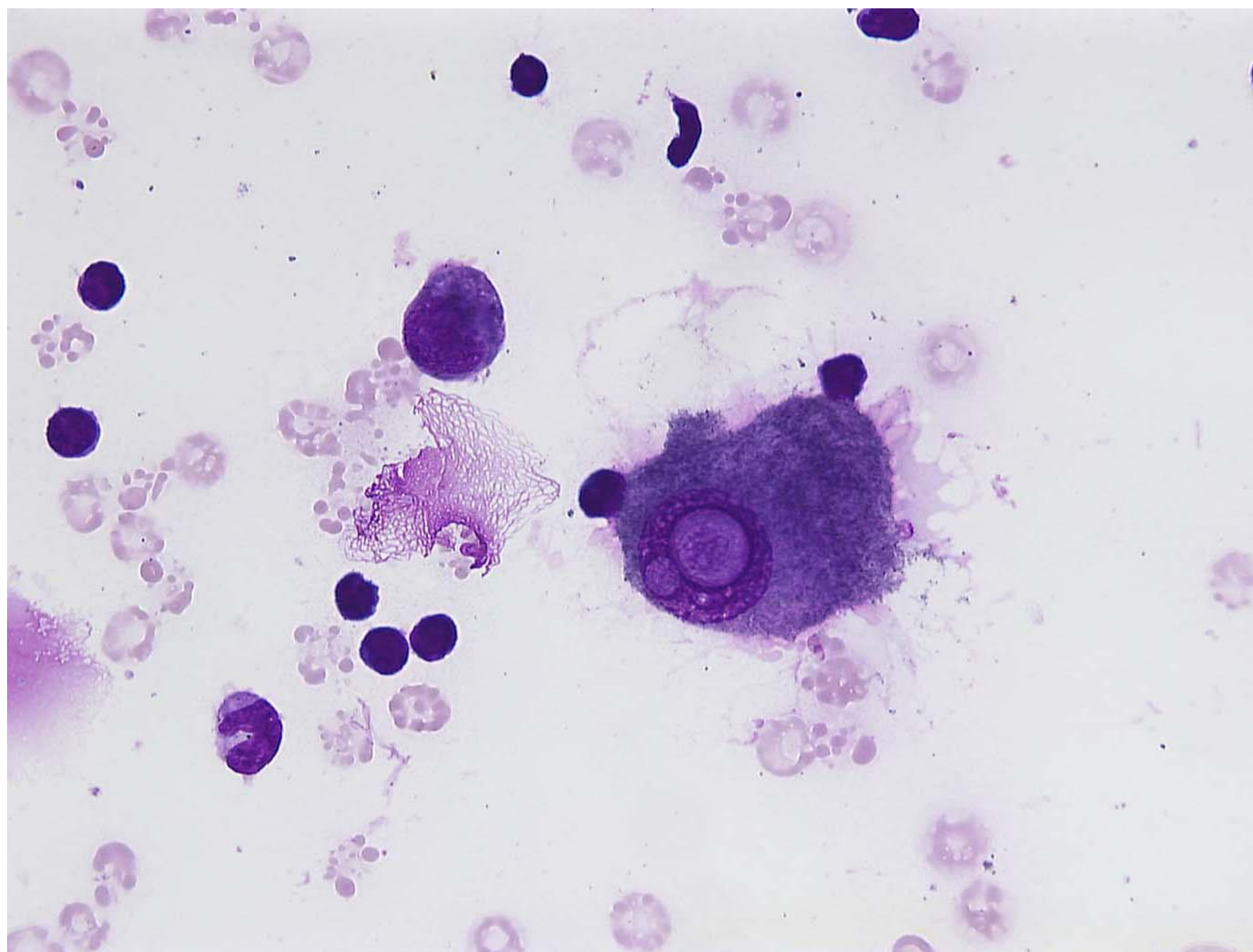
Fig. 2. May-Grünwald-Giemsa stain (MGG), obj.
x63



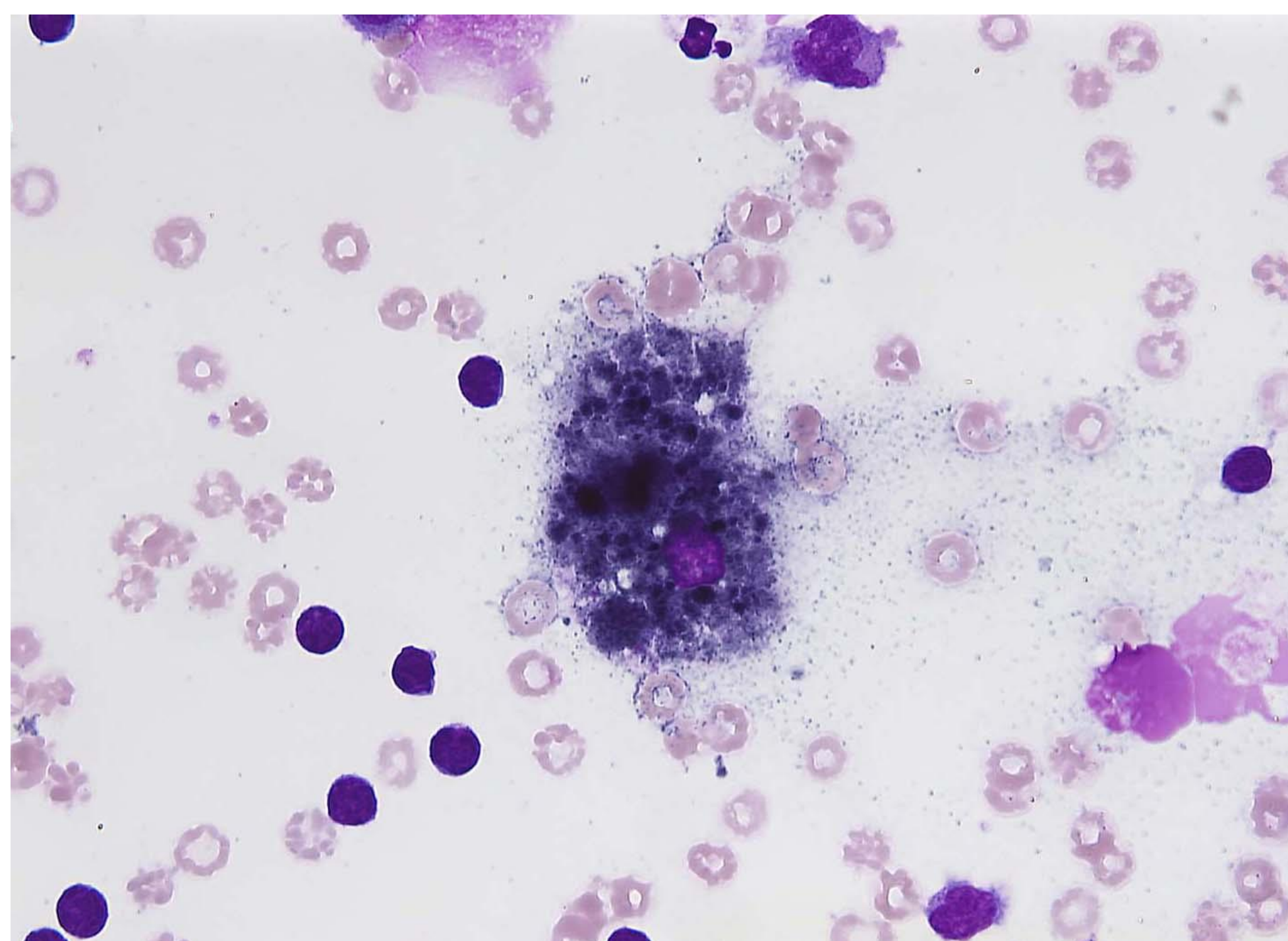
Case Challenges!

2

**Fig. 3. May-Grünwald-Giemsa stain (MGG),
obj. x63**



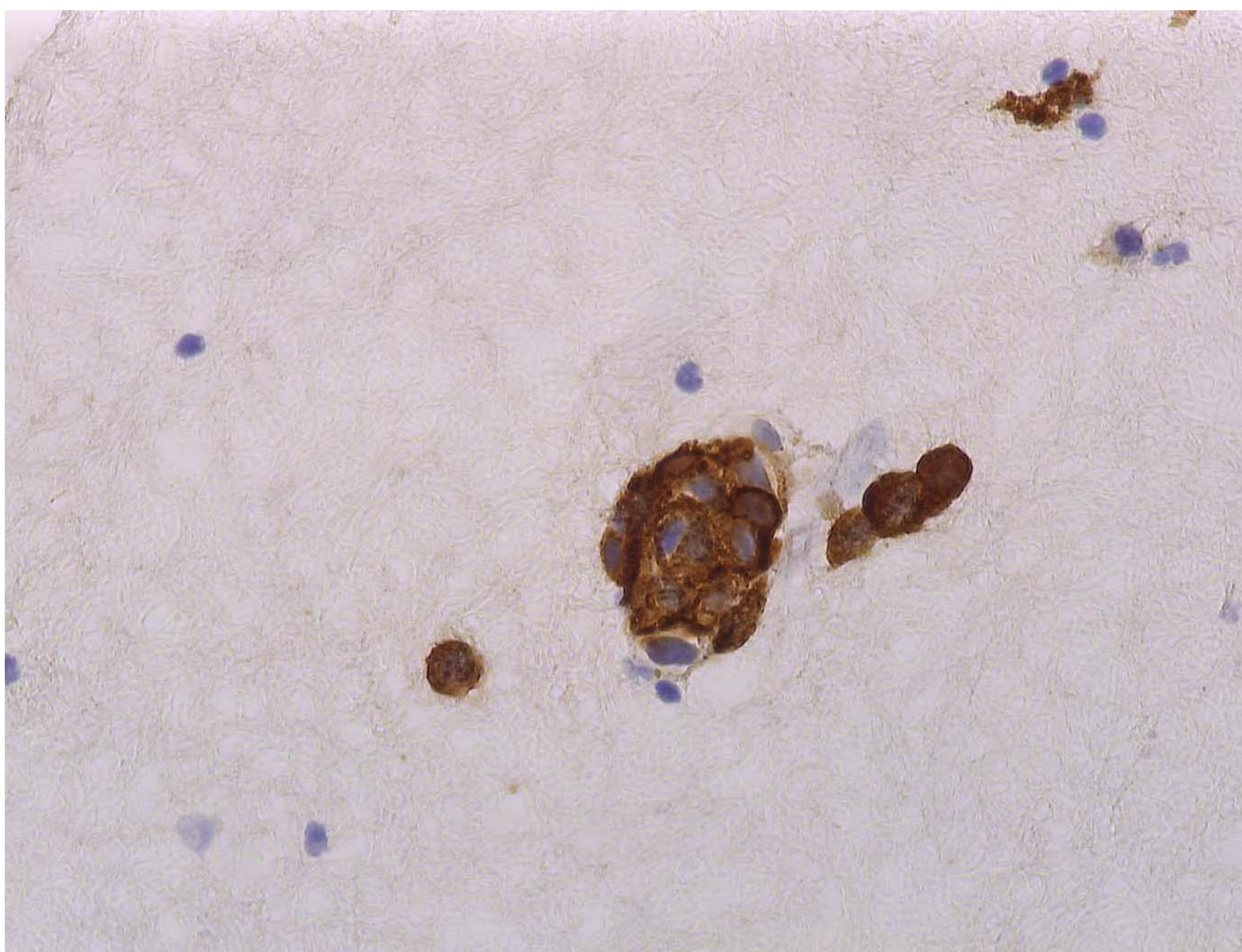
**Fig. 4. May-Grünwald-Giemsa stain (MGG),
obj. x63**



Case Challenges!

2

**Fig. 5. Cell block,
HMB45,
obj. x40**





Case Challenges!

2

Male patient, 47 years, pleural effusion.

History of malignant melanoma, primary manifestation as a tumor of the abdominal wall, primary diagnosis two years ago. Now pleural effusion.

QUESTIONS

- a) Describe what you see.
- b) What does it represent?
- c) What is its significance?

Case Challenges!

2

Male patient, 47 years, pleural effusion.

History of malignant melanoma, primary manifestation as a tumor of the abdominal wall, primary diagnosis two years ago. Now pleural effusion.

ANSWERS

a) Sediment smears of pleural effusion, moderate cellularity. One normal mesothelial cell (fig. 2), some lymphocytes. In moderate numbers atypical cells with large nuclei, a prominent macronucleolus and fine pigmented granula in the cytoplasm. Large nuclear inclusions in one of the atypical cells (fig. 3). A macrophage with coarse dark granules (fig. 4). The atypical cells are positive for HMB-45 (fig. 5).

b) Malignant pleural effusion in malignant melanoma.

c) Cytomorphology and immunchemistry are typical for malignant melanoma. Depending on cellularity in the effusion sample a complete molecular analysis may be possible using effusion fluid.

Final diagnosis: Malignant pleural effusion in malignant melanoma.

Comment: In this case a pleural biopsy was obtained in the same session. In the biopsy molecular analyses have been done revealing an activating BRAF V600E mutation.

Author of the case:

Marianne Engels

Chair of EFCS Educational Committee

EFCS president-elect

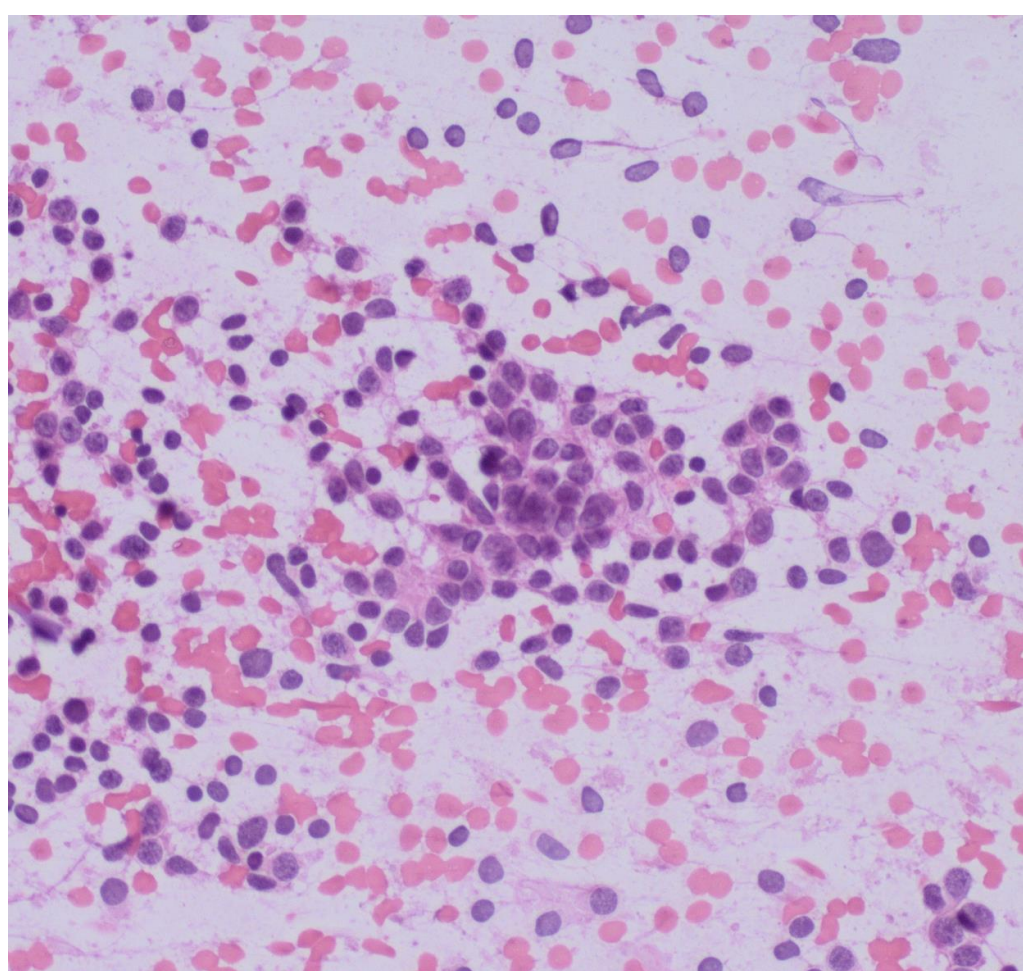
References:

Ikeda K, Tate G, Iezumi K, Suzuki T, Kitamura T, Mitsuya T. Effusion cytomorphology and immunocytochemistry of malignant melanoma: five cases of melanotic melanoma and one case of amelanotic melanoma. *Diagn Cytopathol.* 2009 Jul;37(7):516-21. doi: 10.1002/dc.21054. PMID: 19301358.

Miki Y, Tabatabai ZL, Davidson B. Malignant-Secondary (MAL-S). In: *The International System for Serous Fluid Cytopathology.* Chandra A, Crothers B, Kurtycz D, Schmitt F (eds). Cham 2020.

Shield P, Ribu DL. Cytologic findings in serous effusion specimens from melanoma patients. *Acta Cytol.* 2023 Mar 30. doi: 10.1159/000530427. Epub ahead of print. PMID: 36996775.

Trivial Facts of Cytopathology



Medulloblastoma. Intraoperative
squash smear cytology

Did you know that squash cytology was first introduced by the neuropathologist Dr. Louise Eisenhardt and neurosurgeon Dr. Harvey Cushing in 1930s?

The soft consistency of the central nervous system makes this technique an indispensable tool in intraoperative consultations of brain tumors. The Cushing -Eisenhardt collaboration funded the first Brain tumor registry and Neuropathology collection. At the time, Dr. Cushing along Dr. Eisenhardt and Dr. Bailey published one of the most fundamental and serious attempts to classify brain tumors on a histological basis correlated with patient prognosis!

Found out more in

<https://thejns.org/view/journals/j-neurosurg/50/1/article-p13.xml>

<https://medicine.yale.edu/surgery/neuropathology/cushing/>

Despina Argyropoulou
Residents and YEFCS Committee

Thank you for your time!

Please send your feedback to residentsyoung@efcs.eu

Check our Twitter accounts: @CytologyEFCS and @efcsyoung



EFCS
European Federation of
Cytology Societies

The EFCS Newsletter



Expected Release Date of the
Next Issue:
December 2023